

Protocol for the Examination of Specimens from Patients with Invasive Carcinoma of the Breast

Protocol applies to all invasive carcinomas of the breast, including ductal carcinoma in situ (DCIS) with microinvasion.

Based on AJCC/UICC TNM, 7th edition
Protocol web posting date: October 2009

Procedures

- Complete Excision (Less Than Total Mastectomy, Including Specimens Designated Biopsy, Lumpectomy, Quadrantectomy, and Partial Mastectomy) With or Without Axillary Contents
- Mastectomy (Total, Modified Radical, Radical) With or Without Axillary Contents

Authors

Susan C. Lester, MD, PhD, FCAP*
Department of Pathology, Brigham and Women's Hospital, Boston, Massachusetts

Shikha Bose, MD, FCAP
Department of Pathology and Laboratory Medicine, Cedars-Sinai Medical Center, Los Angeles, California

Yunn-Yi Chen, MD, PhD, FCAP
Department of Pathology, UCSF Medical Center, San Francisco, California

James L. Connolly, MD, FCAP
Department of Pathology, Beth Israel Deaconess Medical Center, Boston, Massachusetts

Monica E. de Baca, MD, FCAP
Physicians Laboratory, Sioux Falls, South Dakota

Patrick L. Fitzgibbons, MD, FCAP
Department of Pathology, St. Jude Medical Center, Fullerton, California

Daniel F. Hayes, MD, Department of Medical Oncology, University of Michigan Medical Center, Ann Arbor, Michigan

Celina Kleer, MD, FCAP
Department of Pathology, University of Michigan Medical Center, Ann Arbor, Michigan

Frances P. O'Malley, MD, FCAP
Department of Pathology, Mount Sinai Hospital, Toronto, Ontario, Canada

David L. Page, MD, FCAP
Department of Pathology, Vanderbilt University Medical Center, Nashville, Tennessee

Barbara L. Smith, MD, PhD
Department of Surgical Oncology, Massachusetts General Hospital, Boston, Massachusetts

Lee K. Tan, MD
Department of Pathology, Memorial Sloan-Kettering Cancer Center, New York, New York

Donald L. Weaver, MD, FCAP
Department of Pathology, College of Medicine and Vermont Cancer Center, University of Vermont, Burlington, Vermont

Eric Winer, MD
Department of Medical Oncology, Dana-Farber Cancer Institute, Boston, Massachusetts

For the Members of the Cancer Committee, College of American Pathologists

* Denotes primary and senior author. All other contributing authors are listed alphabetically.

Previous lead contributors: Donald E. Henson, MD; Harold A. Oberman, MD; Robert V.P. Hutter, MD

© 2009 College of American Pathologists (CAP). All rights reserved.

The College does not permit reproduction of any substantial portion of these protocols without its written authorization. The College hereby authorizes use of these protocols by physicians and other health care providers in reporting on surgical specimens, in teaching, and in carrying out medical research for nonprofit purposes. This authorization does not extend to reproduction or other use of any substantial portion of these protocols for commercial purposes without the written consent of the College.

The CAP also authorizes physicians and other health care practitioners to make modified versions of the Protocols solely for their individual use in reporting on surgical specimens for individual patients, teaching, and carrying out medical research for non-profit purposes.

The CAP further authorizes the following uses by physicians and other health care practitioners, in reporting on surgical specimens for individual patients, in teaching, and in carrying out medical research for non-profit purposes: (1) **Dictation** from the original or modified protocols for the purposes of creating a text-based patient record on paper, or in a word processing document; (2) **Copying** from the original or modified protocols into a text-based patient record on paper, or in a word processing document; (3) The use of a **computerized system** for items (1) and (2), provided that the Protocol data is stored intact as a single text-based document, and is not stored as multiple discrete data fields.

Other than uses (1), (2), and (3) above, the CAP does not authorize any use of the Protocols in electronic medical records systems, pathology informatics systems, cancer registry computer systems, computerized databases, mappings between coding works, or any computerized system without a written license from CAP. Applications for such a license should be addressed to the SNOMED Terminology Solutions division of the CAP.

Any public dissemination of the original or modified Protocols is prohibited without a written license from the CAP.

The College of American Pathologists offers these protocols to assist pathologists in providing clinically useful and relevant information when reporting results of surgical specimen examinations of surgical specimens. The College regards the reporting elements in the "Surgical Pathology Cancer Case Summary (Checklist)" portion of the protocols as essential elements of the pathology report. However, the manner in which these elements are reported is at the discretion of each specific pathologist, taking into account clinician preferences, institutional policies, and individual practice.

The College developed these protocols as an educational tool to assist pathologists in the useful reporting of relevant information. It did not issue the protocols for use in litigation, reimbursement, or other contexts. Nevertheless, the College recognizes that the protocols might be used by hospitals, attorneys, payers, and others. Indeed, effective January 1, 2004, the Commission on Cancer of the American College of Surgeons mandated the use of the checklist elements of the protocols as part of its Cancer Program Standards for Approved Cancer Programs. Therefore, it becomes even more important for pathologists to familiarize themselves with these documents. At the same time, the College cautions that use of the protocols other than for their intended educational purpose may involve additional considerations that are beyond the scope of this document.

The inclusion of a product name or service in a CAP publication should not be construed as an endorsement of such product or service, nor is failure to include the name of a product or service to be construed as disapproval.

CAP Invasive Breast Carcinoma Protocol Revision History

Version Code

The definition of the version code can be found at www.cap.org/cancerprotocols.

Version: InvasiveBreast 3.0.0.0 October 2009

Summary of Changes

No changes have been made since the October 2009 release.

Surgical Pathology Cancer Case Summary (Checklist)

Protocol web posting date: October 2009

INVASIVE CARCINOMA OF THE BREAST: Complete Excision (Less Than Total Mastectomy, Including Specimens Designated Biopsy, Lumpectomy, Quadrantectomy, and Partial Mastectomy With or Without Axillary Contents) and Mastectomy (Total, Modified Radical, Radical With or Without Axillary Contents)

Select a single response unless otherwise indicated.

Specimen (Note A)

- Partial breast
 Total breast (including nipple and skin)
 Other (specify): _____
 Not specified

Procedure (Note A)

- Excision without wire-guided localization
 Excision with wire-guided localization
 Total mastectomy (including nipple and skin)
 Other (specify): _____
 Not specified

Lymph Node Sampling (select all that apply) (Note B)

- No lymph nodes present
 Sentinel lymph node(s)
 Axillary dissection (partial or complete dissection)
 Lymph nodes present within the breast specimen (ie, intramammary lymph nodes)
 Other lymph nodes (eg, supraclavicular or location not identified)
 Specify location, if provided: _____

Specimen Integrity (Note C)

- Single intact specimen (margins can be evaluated)
 Multiple designated specimens (eg, main excision and identified margins)
 Fragmented (margins cannot be evaluated with certainty)
 Other (specify): _____

Specimen Size (for excisions less than total mastectomy) (Note C)

- Greatest dimension: ___ cm
 *Additional dimensions: ___ x ___ cm
 Cannot be determined

* Data elements with asterisks are not required. However, these elements may be clinically important but are not yet validated or regularly used in patient management.

Specimen Laterality

- Right
 Left
 Not specified

***Tumor Site: Invasive Carcinoma (select all that apply) (Note D)**

- Upper outer quadrant
 Lower outer quadrant
 Upper inner quadrant
 Lower inner quadrant
 Central
 Nipple
 *Position: o'clock
 Other (specify): _____
 Not specified

Tumor Size: Size of Largest Invasive Carcinoma (Note E)

- Microinvasion only (≤ 0.1 cm)
 Greatest dimension of largest focus of invasion over 0.1 cm: cm
 *Additional dimensions: x cm
 No residual invasive carcinoma after presurgical (neoadjuvant) therapy
 Cannot be determined (see Comment)

Note: The size of the invasive carcinoma should take into consideration the gross findings correlated with the microscopic examination. In some cases, it may be helpful to use information about tumor size from imaging studies. If multiple foci of invasion are present, the size listed is the size of the largest contiguous area of invasion. The size of multiple invasive carcinomas should not be added together. The size does not include adjacent DCIS.

If there has been a prior core needle biopsy or incisional biopsy showing a larger area of invasion than in the excisional specimen, the largest dimension of the invasive carcinoma in the prior specimen should be used for T classification, if known.

If there has been prior treatment and no invasive carcinoma is present, the cancer is classified as Tis if there is residual DCIS and T0 if there is no remaining carcinoma.

Tumor Focality (Note F)

- Single focus of invasive carcinoma
 Multiple foci of invasive carcinoma
 *Number of foci: _____
 *Sizes of individual foci: _____
 No residual invasive carcinoma after presurgical (neoadjuvant) therapy
 Indeterminate

Note: If there are multiple invasive carcinomas, size, grade, histologic type, and the results of studies for estrogen receptor (ER), progesterone receptor (PR), and HER2/neu should pertain to the largest invasive carcinoma. If smaller invasive carcinomas differ in any of these features, this information may be included in the "Comments" section.

* Data elements with asterisks are not required. However, these elements may be clinically important but are not yet validated or regularly used in patient management.

Macroscopic and Microscopic Extent of Tumor (select all that apply) (Note G)Skin

- Skin is not present
- Invasive carcinoma does not invade into the dermis or epidermis
- Invasive carcinoma directly invades into the dermis or epidermis without skin ulceration
- Invasive carcinoma directly invades into the dermis or epidermis with skin ulceration (classified as T4b)
- Satellite skin foci of invasive carcinoma are present (ie, not contiguous with the invasive carcinoma in the breast) (classified as T4b)

Nipple

- DCIS does not involve the nipple epidermis
- DCIS involves nipple epidermis (Paget disease of the nipple)

Note: This finding does not change the T classification.

Skeletal Muscle

- No skeletal muscle present
- Skeletal muscle is present and is free of carcinoma
- Carcinoma invades skeletal muscle
- Carcinoma invades into skeletal muscle and into the chest wall (classified as T4a)

Note: Invasion into pectoralis muscle is not considered chest wall invasion, and cancers are not classified as T4a unless there is invasion deeper than this muscle.

Ductal Carcinoma In Situ (DCIS) (select all that apply) (Note G)

- No DCIS is present
- DCIS is present
- Extensive intraductal component (EIC) negative
- EIC positive
- Only DCIS is present after presurgical (neoadjuvant) therapy

*Size (Extent) of DCIS

*Estimated size (extent) of DCIS (greatest dimension using gross and microscopic evaluation) is at least ___ cm

*Additional dimensions: ___ x ___ cm

*Number of blocks with DCIS: ___

*Number of blocks examined: ___

Note: The size (extent) of DCIS is an estimation of the volume of breast tissue occupied by DCIS. This information may be helpful for cases with a predominant component of DCIS (eg, DCIS with microinvasion) but may not be necessary for cases of EIC negative invasive carcinomas.

* Data elements with asterisks are not required. However, these elements may be clinically important but are not yet validated or regularly used in patient management.

***Architectural Patterns**

- * Comedo
- * Paget disease (DCIS involving nipple skin)
- * Cribriform
- * Micropapillary
- * Papillary
- * Solid
- * Other (specify): _____

***Nuclear Grade**

- * Grade I (low)
- * Grade II (intermediate)
- * Grade III (high)

***Necrosis**

- * Not identified
- * Present, focal (small foci or single cell necrosis)
- * Present, central (expansive “comedo” necrosis)

Lobular Carcinoma In Situ (LCIS)

- Not identified
- Present

Histologic Type of Invasive Carcinoma (Note H)

- Ductal carcinoma in situ with microinvasion
- Lobular carcinoma in situ with microinvasion
- Ductal carcinoma in situ involving nipple skin (Paget disease) with microinvasion
- Invasive ductal carcinoma (no special type or not otherwise specified)
- Invasive lobular carcinoma
- Invasive carcinoma with ductal and lobular features (“mixed type carcinoma”)
- Invasive mucinous carcinoma
- Invasive medullary carcinoma
- Invasive papillary carcinoma
- Invasive micropapillary carcinoma
- Invasive tubular carcinoma
- Invasive cribriform carcinoma
- Invasive carcinoma, type cannot be determined
- No residual invasive carcinoma after presurgical (neoadjuvant) therapy
- Other(s) (specify): _____

Note: The histologic type corresponds to the largest area of invasion. If there are smaller foci of invasion of a different type, this information should be included under “Additional Pathologic Findings.”

* Data elements with asterisks are not required. However, these elements may be clinically important but are not yet validated or regularly used in patient management.

Histologic Grade: Nottingham Histologic Score (Note I)Glandular (Acinar)/Tubular Differentiation

- Score 1: >75% of tumor area forming glandular/tubular structures
 Score 2: 10% to 75% of tumor area forming glandular/tubular structures
 Score 3: <10% of tumor area forming glandular/tubular structures
 Only microinvasion present (not graded)
 No residual invasive carcinoma after presurgical (neoadjuvant) therapy
 Score cannot be determined

Nuclear Pleomorphism

- Score 1: Nuclei small with little increase in size in comparison with normal breast epithelial cells, regular outlines, uniform nuclear chromatin, little variation in size
 Score 2: Cells larger than normal with open vesicular nuclei, visible nucleoli, and moderate variability in both size and shape
 Score 3: Vesicular nuclei, often with prominent nucleoli, exhibiting marked variation in size and shape, occasionally with very large and bizarre forms
 Only microinvasion present (not graded)
 No residual invasive carcinoma after presurgical (neoadjuvant) therapy
 Score cannot be determined

Mitotic Count

- Score 1 (see Table 2)
 Score 2 (see Table 2)
 Score 3 (see Table 2)
 Only microinvasion present (not graded)
 No residual invasive carcinoma after presurgical (neoadjuvant) therapy
 Score cannot be determined

*Number of mitoses per 10 high-power fields: ____

*Diameter of microscope field: ____ mm

Overall Grade

- Grade 1: scores of 3, 4, or 5
 Grade 2: scores of 6 or 7
 Grade 3: scores of 8 or 9
 Only microinvasion present (not graded)
 No residual invasive carcinoma after presurgical (neoadjuvant) therapy
 Score cannot be determined.

Note: The grade corresponds to the largest area of invasion. If there are smaller foci of invasion of a different grade, this information should be included under "Additional Pathologic Findings."

* Data elements with asterisks are not required. However, these elements may be clinically important but are not yet validated or regularly used in patient management.

Margins (select all that apply) (Note J)

Margins cannot be assessed

Margins uninvolved by invasive carcinoma

Distance from closest margin: mm

*Specify margins:

*Distance from superior margin: mm

*Distance from inferior margin: mm

*Distance from anterior margin: mm

*Distance from posterior margin: mm

*Distance from medial margin: mm

*Distance from lateral margin: mm

*Distance from other specified margin: mm

*Designation of margin: _____

Margins uninvolved by DCIS (if present)

Distance from closest margin: mm

*Specify margins:

*Distance from superior margin: mm

*Distance from inferior margin: mm

*Distance from anterior margin: mm

*Distance from posterior margin: mm

*Distance from medial margin: mm

*Distance from lateral margin: mm

*Distance from other specified margin: mm

*Designation of margin: _____

Margin(s) positive for invasive carcinoma

*Specify margin(s): _____

*Specify margin(s) and extent of involvement:

* Superior margin

* Focal

* Minimal/moderate

* Extensive

* Inferior margin

* Focal

* Minimal/moderate

* Extensive

* Anterior margin

* Focal

* Minimal/moderate

* Extensive

* Posterior margin

* Focal

* Minimal/moderate

* Extensive

* Data elements with asterisks are not required. However, these elements may be clinically important but are not yet validated or regularly used in patient management.

- * ___ Medial margin
 - * ___ Focal
 - * ___ Minimal/moderate
 - * ___ Extensive
- * ___ Lateral margin
 - * ___ Focal
 - * ___ Minimal/moderate
 - * ___ Extensive

___ Margin(s) positive for DCIS

*Specify margin(s): _____

*Specify margin(s) and extent of involvement:

- * ___ Superior margin
 - * ___ Focal
 - * ___ Minimal/moderate
 - * ___ Extensive
- * ___ Inferior margin
 - * ___ Focal
 - * ___ Minimal/moderate
 - * ___ Extensive
- * ___ Anterior margin
 - * ___ Focal
 - * ___ Minimal/moderate
 - * ___ Extensive
- * ___ Posterior margin
 - * ___ Focal
 - * ___ Minimal/moderate
 - * ___ Extensive
- * ___ Medial margin
 - * ___ Focal
 - * ___ Minimal/moderate
 - * ___ Extensive
- * ___ Lateral margin
 - * ___ Focal
 - * ___ Minimal/moderate
 - * ___ Extensive

***Treatment Effect: Response to Presurgical (Neoadjuvant) Therapy (Note K)**

*In the Breast

- * ___ No known presurgical therapy
- * ___ No definite response to presurgical therapy in the invasive carcinoma
- * ___ Probable or definite response to presurgical therapy in the invasive carcinoma
- * ___ No residual invasive carcinoma is present in the breast after presurgical therapy

* Data elements with asterisks are not required. However, these elements may be clinically important but are not yet validated or regularly used in patient management.

*In the Lymph Nodes

- * ___ No known presurgical therapy
- * ___ No lymph nodes removed
- * ___ No definite response to presurgical therapy in metastatic carcinoma
- * ___ Probable or definite response to presurgical therapy in metastatic carcinoma
- * ___ No lymph node metastases. Fibrous scarring, possibly related to prior lymph node metastases with pathologic complete response
- * ___ No lymph node metastases and no prominent fibrous scarring in the nodes

***Lymph-Vascular Invasion (Note L)**

- * ___ Not identified
- * ___ Present
- * ___ Indeterminate

*Dermal Lymph-Vascular Invasion

- * ___ No skin present
- * ___ Not identified
- * ___ Present
- * ___ Indeterminate

Lymph Nodes (required only if lymph nodes are present in the specimen) (Note B)

Number of sentinel lymph nodes examined: ___

Total number of lymph nodes examined (sentinel and nonsentinel): ___

Number of lymph nodes with macrometastases (>0.2 cm): ___

Number of lymph nodes with micrometastases (>0.2 mm to 0.2 cm and/or >200 cells): ___

Number of lymph nodes with isolated tumor cells (\leq 0.2 mm and \leq 200 cells): ___

Size of largest metastatic deposit (if present): ___

Note: The sentinel node is usually the first involved lymph node. In the unusual situation in which a sentinel node is not involved by metastatic carcinoma, but a nonsentinel node is involved, this information should be included in a note.

*Extranodal Extension

- * ___ Present
- * ___ Not identified
- * ___ Indeterminate

*Method of Evaluation of Sentinel Lymph Nodes (select all that apply)

- * ___ Hematoxylin and eosin (H&E), one level
- * ___ H&E, multiple levels
- * ___ Immunohistochemistry
- * ___ Sentinel lymph node biopsy not performed
- * ___ Other (specify): _____

Pathologic Staging (based on information available to the pathologist) (pTNM) (Note M)

TNM Descriptors (required only if applicable) (select all that apply)

m (multiple foci of invasive carcinoma)

r (recurrent)

y (posttreatment)

Primary Tumor (Invasive Carcinoma) (pT)

pTX: Primary tumor cannot be assessed

pT0: No evidence of primary tumor[#]

pTis (DCIS): Ductal carcinoma in situ[#]

pTis (LCIS): Lobular carcinoma in situ[#]

pTis (Paget): Paget disease of the nipple *not* associated with invasive carcinoma and/or carcinoma in situ (DCIS and/or LCIS) in the underlying breast parenchyma[#]

pT1: Tumor ≤20 mm in greatest dimension

pT1mi: Tumor ≤1 mm in greatest dimension (microinvasion)

pT1a: Tumor >1 mm but ≤5 mm in greatest dimension

pT1b: Tumor >5 mm but ≤10 mm in greatest dimension

pT1c: Tumor >10 mm but ≤20 mm in greatest dimension

pT2: Tumor >20 mm but ≤50 mm in greatest dimension

pT3: Tumor >50 mm in greatest dimension

pT4: Tumor of any size with direct extension to the chest wall and/or to the skin (ulceration or skin nodules). *Note:* Invasion of the dermis alone does not qualify as pT4.

pT4a: Extension to chest wall, not including only pectoralis muscle adherence/invasion

pT4b: Ulceration and/or ipsilateral satellite nodules and/or edema (including peau d'orange) of the skin which do not meet the criteria for inflammatory carcinoma

pT4c: Both T4a and T4b

pT4d: Inflammatory carcinoma^{##}

[#] For the purposes of this checklist, these categories should only be used in the setting of preoperative (neoadjuvant) therapy for which a previously diagnosed invasive carcinoma is no longer present after treatment.

^{##} Inflammatory carcinoma is a clinical-pathologic entity characterized by diffuse erythema and edema (peau d'orange) involving one-third or more of the skin of the breast. The skin changes are due to lymphedema caused by tumor emboli within dermal lymphatics, which may or may not be obvious in a small skin biopsy. However, a tissue diagnosis is still necessary to demonstrate an invasive carcinoma in the underlying breast parenchyma or at least in the dermal lymphatics, as well as to determine biological markers, such as ER, PR, and HER2 status. Tumor emboli in dermal lymphatics without the clinical skin changes described above do not qualify as inflammatory carcinoma. Locally advanced breast cancers directly invading the dermis or ulcerating the skin without the clinical skin changes and tumor emboli in dermal lymphatics also do not qualify as inflammatory carcinoma. Thus the term inflammatory carcinoma should not be applied to neglected locally advanced cancer of the breast presenting late in the course of a patient's disease. The rare case that exhibits all the features of inflammatory carcinoma, but in which skin changes involve less than one-third of the skin, should be classified by the size and extent of the underlying carcinoma.

* Data elements with asterisks are not required. However, these elements may be clinically important but are not yet validated or regularly used in patient management.

Regional Lymph Nodes (pN) (choose a category based on lymph nodes received with the specimen; immunohistochemistry and/or molecular studies are not required)

If internal mammary lymph nodes, infraclavicular nodes, or supraclavicular lymph nodes are included in the specimen, consult the *AJCC Cancer Staging Manual*¹ for additional lymph node categories.

Modifier (required only if applicable)

___ (sn): Only sentinel node(s) evaluated. If 6 or more sentinel nodes and/or nonsentinel nodes are removed, this modifier should not be used.

Category (pN)

___ pNX: Regional lymph nodes cannot be assessed (eg, previously removed, or not removed for pathologic study)

___ pN0: No regional lymph node metastasis identified histologically
Note: Isolated tumor cell (ITC) clusters are defined as small clusters of cells not greater than 0.2 mm or single tumor cells, or a cluster of fewer than 200 cells in a single histologic cross-section.[#] ITCs may be detected by routine histology or by immunohistochemical (IHC) methods. Nodes containing only ITCs are excluded from the total positive node count for purposes of N classification but should be included in the total number of nodes evaluated.

___ pN0 (i-): No regional lymph node metastases histologically, negative IHC

___ pN0 (i+): Malignant cells in regional lymph node(s) no greater than 0.2 mm and no more than 200 cells (detected by H&E or IHC including ITC)

___ pN0 (mol-): No regional lymph node metastases histologically, negative molecular findings (reverse transcriptase polymerase chain reaction [RT-PCR])

___ pN0 (mol+): Positive molecular findings (RT-PCR), but no regional lymph node metastases detected by histology or IHC

___ pN1mi: Micrometastases (greater than 0.2 mm and/or more than 200 cells, but none greater than 2.0 mm).

___ pN1a: Metastases in 1 to 3 axillary lymph nodes, at least 1 metastasis greater than 2.0 mm

___ pN2a: Metastases in 4 to 9 axillary lymph nodes (at least 1 tumor deposit greater than 2.0 mm)

___ pN3a: Metastases in 10 or more axillary lymph nodes (at least 1 tumor deposit greater than 2.0 mm)

[#] *Approximately 1000 tumor cells are contained in a 3-dimensional 0.2-mm cluster. Thus, if more than 200 individual tumor cells are identified as single dispersed tumor cells or as a nearly confluent elliptical or spherical focus in a single histologic section of a lymph node, there is a high probability that more than 1000 cells are present in the node. In these situations, the node should be classified as containing a micrometastasis (pN1mi). Cells in different lymph node cross-sections or longitudinal sections or levels of the block are not added together; the 200 cells must be in a single node profile even if the node has been thinly sectioned into multiple slices. It is recognized that there is substantial overlap between the upper limit of the ITC and the lower limit of the micrometastasis categories because of inherent limitations in pathologic nodal evaluation and detection of minimal tumor burden in lymph nodes. Thus, the threshold of 200 cells in a single cross-section is a guideline to help pathologists distinguish between these 2 categories.*

* Data elements with asterisks are not required. However, these elements may be clinically important but are not yet validated or regularly used in patient management.

The pathologist should use judgment regarding whether it is likely that the cluster of cells represents a true micrometastasis or is simply a small group of isolated tumor cells.

Distant Metastasis (M)

- Not applicable
- cM0(i+): No clinical or radiographic evidence of distant metastasis, but deposits of molecularly or microscopically detected tumor cells in circulating blood, bone marrow, or other nonregional nodal tissue that are ≤ 0.2 mm in a patient without symptoms or signs of metastasis
- pM1: Distant detectable metastasis as determined by classic clinical and radiographic means and/or histologically proven > 0.2 mm

***Additional Pathologic Findings (Note N)**

*Specify: _____

Ancillary Studies (Note O)

Estrogen Receptor (immunohistochemical results on invasive carcinoma performed on this specimen or a prior core needle biopsy or incisional biopsy)

- Performed on this specimen
- Performed on another specimen
*Specify specimen (accession number): _____
- Pending
- Not performed
- No residual invasive carcinoma after presurgical (neoadjuvant) therapy
- Other (specify): _____

Results:

- Immunoreactive tumor cells present ($\geq 1\%$)
Quantitation: _____
- Less than 1% immunoreactive cells present
- No immunoreactive tumor cells present
- Results unknown
- Other (specify): _____

*Antibody vendor and clone: _____

*Type of fixative (if other than neutral buffered formalin): _____

Progesterone Receptor (immunohistochemical results for invasive carcinoma performed on this specimen or a prior core needle biopsy or incisional biopsy)

- Performed on this specimen
- Performed on another specimen
*Specify specimen (accession number): _____
- Pending
- Not performed
- No residual invasive carcinoma after presurgical (neoadjuvant) therapy
- Other (specify): _____

* Data elements with asterisks are not required. However, these elements may be clinically important but are not yet validated or regularly used in patient management.

Results:

- Immunoreactive tumor cells present (≥1%)
 Quantitation: _____
- Less than 1% immunoreactive cells present
- No immunoreactive tumor cells present
- Results unknown
- Other (specify): _____

*Antibody vendor and clone: _____

HER2/neu (results for invasive carcinoma performed on this specimen or a prior core needle biopsy or incisional biopsy)

Immunoperoxidase Studies

- Performed on this specimen
- Performed on another specimen
 *Specify specimen (accession number): _____
- Pending
- Not performed
- No residual invasive carcinoma after presurgical (neoadjuvant) therapy
- Other (specify): _____

Results:

- Negative (Score 0)
- Negative (Score 1+)
- Equivocal (Score 2+)
- Positive (Score 3+)
- Other
 Specify: _____
- Results unknown

*Antibody vendor and clone: _____

Fluorescence In Situ Hybridization (FISH) for HER2/neu

- Performed on this specimen
- Performed on another specimen
 *Specify specimen (accession number): _____
- Pending
- Not performed
- No residual invasive carcinoma after presurgical (neoadjuvant) therapy
- Other (specify): _____

* Data elements with asterisks are not required. However, these elements may be clinically important but are not yet validated or regularly used in patient management.

Results:

- Not amplified (HER2 gene copy <4.0 or ratio <1.8)
 Equivocal (HER2 gene copy 4.0 to 6.0 or ratio 1.8 to 2.2)
 Amplified (HER2 gene copy >6.0 or ratio >2.2)
 *Average number of HER2 gene copies per cell: ____
 *Average number of chromosome 17 per cell: ____
 *Ratio: ____
 Results unknown
 Other (specify): _____

* Name of assay: _____

*Other Ancillary Studies (results for invasive carcinoma performed on this specimen or a prior core needle biopsy or incisional biopsy)

- * Performed on this specimen
 * Performed on another specimen
 *Specify specimen (accession number): _____
 *Name of test: _____
 *Results: _____

***Microcalcifications (select all that apply) (Note P)**

- * Not identified
 * Present in DCIS
 * Present in invasive carcinoma
 * Present in non-neoplastic tissue
 * Present in both carcinoma and non-neoplastic tissue

***Clinical History (select all that apply) (Note Q)**

*The current clinical/radiologic breast findings for which this surgery is performed include:

- * Palpable mass
 * Radiologic finding
 * Mass or architectural distortion
 * Calcifications
 * Other (specify): _____
 * Nipple discharge
 * Other (specify): _____
 * Prior history of breast cancer
 *Specify site, diagnosis, and prior treatment: _____
 * Prior presurgical (neoadjuvant) therapy for this diagnosis of invasive carcinoma
 *Specify type: _____

***Comment(s)**

* Data elements with asterisks are not required. However, these elements may be clinically important but are not yet validated or regularly used in patient management.

Explanatory Notes

A. Breast Specimens and Procedures

The following types of breast specimens and procedures may be reported with the checklist:

Excisions: These procedures resect breast tissue without the intent of removing the entire breast. The nipple is usually not included with excisions. Excisions include specimens designated “partial mastectomies,” “lumpectomies,” and “quadrantectomies.”

- **Wire-guided localization excisions:** If a nonpalpable lesion is detected by mammography, ultrasonography, or magnetic resonance imaging (MRI), a wire is placed to identify the location of the lesion. Specimen radiography or ultrasonography may be used to document the presence of the targeted lesion in the excised tissue. The specimen radiograph (if performed) and the results of the radiologic evaluation should be available to the pathologist when needed. Specimen imaging by radiography or ultrasound usually does not reveal the targeted lesion, if it was clinically only detected by MRI.
- **Excisions without wire localization:** These excisions are generally performed for palpable masses or to excise major ducts behind the nipple to evaluate nipple discharge.

Total Mastectomy: Removal of all breast tissue, generally including the nipple and areola.

- **Simple mastectomy:** This procedure consists of a total mastectomy without removal of axillary lymph nodes.
- **Skin sparing mastectomy:** This is a total mastectomy with removal of the nipple and only a narrow surrounding rim of skin.
- **Nipple sparing mastectomy:** This is a total mastectomy without removal of skin or nipple. The subareolar tissue is examined and the nipple later removed if involved by carcinoma.
- **Modified radical mastectomy:** This procedure consists of a total mastectomy with an axillary dissection. In the checklist, the breast and lymph node specimens are documented separately. A small portion of pectoralis muscle is sometimes removed.
- **Radical mastectomy:** This procedure consists of a total mastectomy with removal of the pectoralis major and pectoralis minor muscles. This type of specimen and procedure can be indicated on the checklist as “Other.”

The checklist is intended for reporting the patient’s specimen with the largest focus of invasive carcinoma. If additional margin excisions are performed in the same procedure, the findings for these specimens can be included in the margin evaluation. If additional smaller foci of invasive carcinoma are present in the main excision or in margin excisions, the characteristics of these carcinomas (ie, size, histologic type, and

grade) should be recorded under “Additional Pathologic Findings.” Additional ancillary studies on smaller foci of carcinoma are recommended if the carcinomas are of different histologic type or grade. If additional margin excisions are performed in a subsequent procedure (eg, on another day), and a larger area of invasive carcinoma is not present, the checklist need not be used.

If a patient has 2 ipsilateral invasive carcinomas removed in 2 separate excisions during the same procedure, the checklist should be used for the larger invasive carcinoma. The pathologic findings for the smaller cancer may be reported without using the checklist. If a patient has 2 ipsilateral invasive carcinomas removed in 2 separate excisions in procedures on different days, the checklist should be used for the larger carcinoma and the American Joint Committee on Cancer (AJCC) T classification will pertain to this carcinoma. If a patient has bilateral breast carcinomas, these would be reported in separate checklists.

If information from other specimens is included in completing the checklist (eg, the results of hormone receptors from a prior core needle biopsy or the finding of lymph node metastases on a previous lymph node biopsy), then this must be clearly stated in the “Comments” section, and the accession numbers of the other cases should be provided.

The following types of specimens should not be reported by using this checklist:

- Very small incisional biopsies (including core needle biopsies).
- Re-excision of a biopsy site after removal of most of the carcinoma.

Specimen sampling for specimens with invasive carcinoma has the following goals²⁻⁶:

- The clinical or radiologic lesion for which the surgery was performed must be examined microscopically. If the lesion is a nonpalpable imaging finding, the specimen radiograph and/or additional radiologic studies may be necessary to identify the lesion. When practical, the entire lesion, or the entire area with the imaging finding, should be submitted in a sequential fashion for histologic examination.
- If the specimen consists predominantly of DCIS with microinvasion, complete submission of the entire specimen, or at a minimum the entire grossly involved area, is recommended to identify additional areas of invasion and/or lymph-vascular invasion.
- All other gross lesions in the specimen must be sampled.
- Each designated margin must be evaluated for involvement by invasive carcinoma and DCIS. If the specimen is received sectioned or fragmented, this should be noted, as this will limit the ability to evaluate the status of margins.

Tissue may be taken for research studies or assays that do not involve the histologic examination of the tissue (eg, RT-PCR) only when taken in such a way as to not compromise the evaluation of the invasive carcinoma and lymph nodes for prognostic factors and margin status.

B. Lymph Node Sampling and Reporting

Most patients with invasive carcinoma will have lymph nodes sampled.

Types of lymph nodes:

- **Sentinel lymph nodes** are identified by the surgeon by uptake of radiotracer or dye or both. Adjacent palpable nonsentinel nodes may also be removed.
- **Axillary lymph nodes** are removed by en bloc resection of axillary tissue. The nodes are divided into levels: I (low-axilla: lateral to the lateral border of the pectoralis minor muscle); II (mid-axilla: between the medial and lateral borders of the pectoralis minor muscle and the interpectoral [Rotter's] lymph nodes); and III (apical axilla or infraclavicular nodes: medial to the medial margin of the pectoralis minor muscle and inferior to the clavicle). A surgeon may choose to remove 1 or more of these levels.
- **Intramammary nodes** are present within breast tissue and are most commonly found in the upper outer quadrant. Intramammary nodes may rarely be sentinel lymph nodes. These nodes are included with axillary nodes for AJCC N classification.
- **Internal mammary nodes, supraclavicular nodes, and infraclavicular nodes** are rarely removed for breast cancer staging. If metastases are present in these nodes, there are specific AJCC N categories (see *AJCC Cancer Staging Manual*¹).

Lymph node sampling:

- **Grossly positive nodes:** The size of grossly positive nodes should be recorded. One section to include any areas suggestive of extranodal invasion is sufficient. Cancerous nodules in the axillary fat adjacent to the breast, without histologic evidence of residual lymph node tissue, are classified as regional lymph node metastasis.
- **Grossly negative nodes:** Sampling must be adequate to detect all macrometastases, as they are known to have prognostic importance (ie, all metastatic deposits >2 mm). Thus, each node should be thinly sliced at 2 mm, and all slices should be submitted for microscopic examination. At least 1 representative H&E level must be examined. Additional methods of sampling such as additional H&E levels or immunohistochemical studies will detect additional nodes with isolated tumor cells or micrometastases. However, the prognostic importance of these small metastases remains under investigation.

The nodes must be submitted in such a way that every node can be evaluated and counted separately. If more than 1 sliced node is placed in the same cassette, each node should be inked a different color for identification.

Reverse transcriptase polymerase chain reaction has been developed as an alternative method for examining lymph nodes.^{7,8} The tissue used for this assay cannot be examined microscopically. All macrometastases must be identified histologically.

Therefore, nodal tissue can only be used for other assays if all macrometastases can be identified by H&E examination. False-positive and false-negative results can occur with RT-PCR. The significance of a positive RT-PCR result for a histologically negative lymph node is unknown.

Reporting lymph nodes:

- **Number of nodes examined:** The total number of nodes includes sentinel nodes, non-sentinel nodes, nodes from axillary dissections, and intramammary nodes. When the number of sentinel and non-sentinel nodes removed is less than six nodes, the AJCC “sn” modifier is used.
- **Size of metastases:** Metastases are classified into 3 groups:
 - Isolated tumor cells (ITCs) are defined as single cells or small clusters of cells not larger than 0.2 mm and no more than 200 cells in a single cross-section, usually with no histologic evidence of malignant activity (eg, proliferation or stromal reaction).⁹ If morphologic techniques (either hematoxylin-eosin or immunohistochemistry) are used to detect ITCs, the regional lymph nodes should be designated as pN0(i+) or pN0(i-), as appropriate. Isolated tumor cells are not included in the total number of positive nodes for N classification.
 - Micrometastases measure more than 0.2 mm, but not more than 2 mm, and/or comprise more than 200 cells in a single cross-section. If only micrometastases are present, the N classification is N1mi. If at least 1 macrometastasis is present, nodes with micrometastases are included in the total node count for N classification.
 - Macrometastases measure more than 2 mm.

In most cases, if metastases are present, the sentinel node will be involved. In rare cases, only nonsentinel nodes contain metastases. These cases can occur if the true sentinel node is completely replaced by tumor (and therefore is not detected by radioactive tracer or dye), if there is unusual lymphatic drainage, or if there is failure of the technique to identify the node. This finding should be included in the report.

In some cases, the best N classification can be difficult to determine (Figure 1):

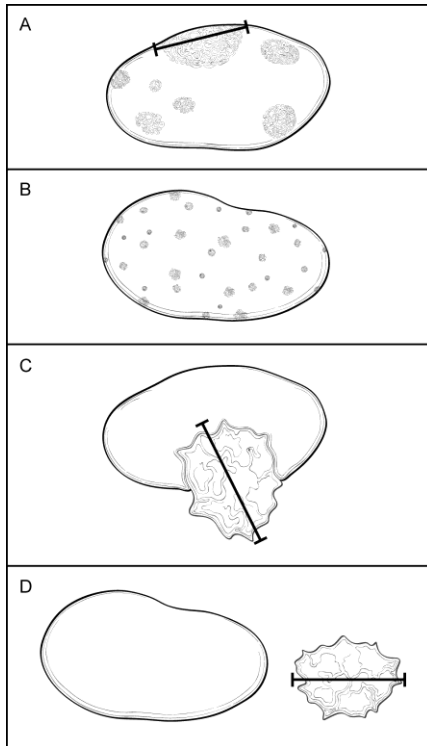


Figure 1. Classification of Lymph Node Metastases. A. Multiple clusters of tumor cells. Classification is based on the size of the largest contiguous cluster of tumor cells. The distance between clusters should not be included in the size measurement. However, if the overall volume of tumor is similar to the next highest nodal category, it is recommended that the pathologist use his or her judgment to assign the best N category and to include the reason for the difficulty in classification in a note. B. Dispersed pattern of lymph node metastasis. Some carcinomas, in particular lobular carcinomas, metastasize as single cells and do not form cohesive clusters. In such cases, the “size” of the metastasis is difficult to determine. If more than 200 tumor cells are present in 1 cross-section of the node, then the category of isolated tumor cells should not be used. If there is difficulty in assigning the N classification, it is recommended that the reason be provided in a note. C. Extranodal invasion. The area of invasion outside the lymph node capsule is included in the overall size of the lymph node metastasis. The size of the metastasis includes the tumor cells and the desmoplastic response (ie, the cells do not need to be contiguous). The finding of extranodal invasion is also reported. D. Cancerous nodules in axillary fat. Areas of carcinoma invading into the stroma in axillary adipose tissue, without residual nodal tissue, are considered to be positive lymph nodes. However, if there is surrounding breast tissue, or ductal carcinoma in situ, then the invasive carcinoma should be classified as an invasive carcinoma and not as a lymph node metastasis.

- Multiple clusters of tumor cells within a lymph node (Figure 1, A):** The “size” of the metastatic deposit for N classification is based on the largest contiguous cluster of tumor cells. However, when the overall volume of tumor is similar to that of the higher nodal category (eg, a node with 9 clusters of tumor cells, each measuring 1 mm), then the pathologist must use his or her judgment in assigning the N category. The size and number of cells used for AJCC classification are meant to be guidelines and not absolute cutoffs. It is recommended that the reason for the difficulty in assigning the N classification be stated in a note.
- Dispersed pattern of lymph node metastasis (Figure 1, B):** Some invasive carcinomas, particularly lobular carcinomas, may metastasize as individual tumor

cells and not as cohesive clusters. It can be difficult to estimate the volume of tumor present for N classification. To avoid underclassification of such cases, an upper limit of 200 cells in 1 node cross-section for “isolated tumor cells” is recommended. Pathologist judgment is required to determine the best N classification.

- **Extranodal (or extracapsular) tumor invasion (Figure 1, C):** Metastatic carcinoma may invade through the lymph node capsule into adjacent adipose tissue. This finding correlates with the clinical impression of fixed or matted nodes when extensive and is a risk factor for recurrence. Extranodal extension should be included when determining the size of a lymph node metastasis. The size of the metastasis includes the tumor cells and the surrounding desmoplastic response (ie, the tumor cells need not be touching). Tumor within lymphatic spaces in the axillary tissue without invasion of adipose tissue is not considered extranodal invasion.
- **Cancerous nodules in axillary adipose tissue (Figure 1, D):** Metastatic carcinoma can completely replace a lymph node. Foci of invasive carcinoma in axillary adipose tissue can be counted as positive lymph nodes. There must be stromal invasion, and carcinoma limited to lymphatic channels is not included. If the carcinoma is surrounded by breast tissue and/or DCIS is present, the area of invasion is more likely to be a carcinoma arising in axillary breast tissue and should not be counted as metastatic carcinoma to a lymph node.
- **Nodes after neoadjuvant therapy:** The response of metastatic carcinoma in lymph nodes after treatment is an important prognostic factor. In addition to the information described above, evidence of treatment response (eg, small tumor deposits within an area of fibrosis) should also be reported (see Note K).

C. Specimen Integrity and Size

It is preferable that the area of carcinoma be removed in a single intact specimen. If the specimen has been incised, or is fragmented, then it may not be possible to accurately assess margins. If invasive carcinoma is present in more than 1 fragment, it may be difficult or impossible to determine the size of the invasive carcinoma or the number of invasive carcinomas present.

The specimen size refers to the main specimen that was excised to remove the cancer. It does not include additional excisions for margin evaluation. The size of these specimens should be documented in the gross description. If the separate margin specimens are oriented, the results of the final margin status can be included in the checklist. If not oriented, the findings can be reported under “Additional Pathologic Findings.”

D. Tumor Site

The site of an invasive carcinoma is helpful to document, when provided by the surgeon, to correlate with prior studies (eg, a core needle biopsy) or with future recurrences. The site can be indicated by quadrant and/or by a clock position.

The approximate tumor site can be determined in a mastectomy. However, it is sometimes difficult to correlate with the position as determined in vivo because of differences in how the specimen would be angled on the chest wall (ie, the skin ellipse

would typically point to the axilla). It is helpful to locate the carcinoma with respect to the clinical site or imaging site, when possible.

If the patient has undergone presurgical (neoadjuvant) therapy and there is no residual invasive carcinoma, the tumor site refers to the location of the prior invasive carcinoma (ie, the tumor bed).

E. Tumor Size (Size of Invasive Carcinoma)

The size of an invasive carcinoma is an important prognostic factor. The single greatest dimension of the largest invasive carcinoma is used to determine T classification (Figure 2, A through F). The best size for AJCC T classification should use information from imaging, gross examination, and microscopic evaluation. Visual determination of size is often unreliable, as carcinomas often blend into adjacent fibrous tissue. The size by palpation of a hard mass correlates better with invasion of tumor cells into stroma with a desmoplastic response. Sizes should be measured to the nearest millimeter. The AJCC recommendation is to round off the size to the millimeter that is closest to the cutoff for AJCC T classification. For example, a size of 1.1 mm would be reported as 1 mm (T1mic) or a size of 2.01 cm would be reported as 2.0 cm (T1c).

In some cases, the size may be difficult to determine.

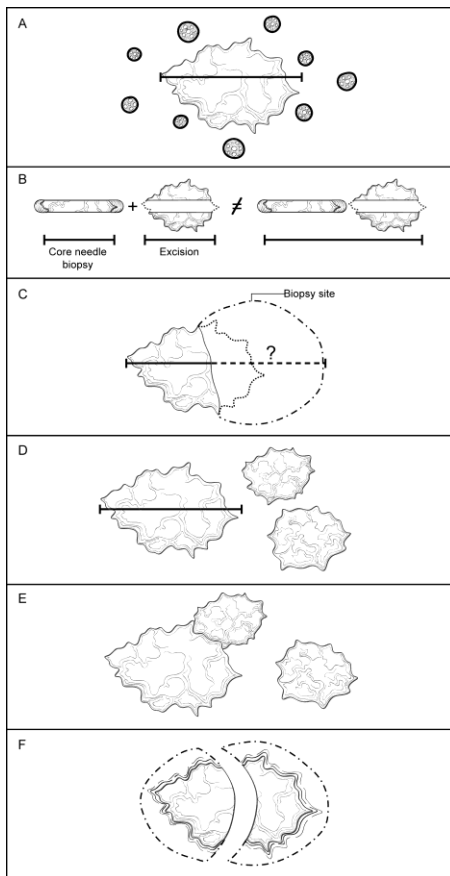


Figure 2. Determining the size of an invasive carcinoma. A. Invasive carcinoma with surrounding ductal carcinoma in situ (DCIS). The size only includes the area of the invasive carcinoma and does not include the adjacent DCIS. The size should be measured to the closest 1 mm. B. Small invasive carcinoma with prior core needle biopsy. The size of the carcinoma in

the core needle biopsy should not be added to the size of the carcinoma in the excisional specimen, as this will generally overestimate the true size. The best size for classification must take into consideration the largest dimension of the carcinoma in both specimens, as well as the size by imaging before the core needle biopsy. C. Small invasive carcinomas with adjacent biopsy site changes. In some excisional specimens, a small carcinoma will be present to a relatively large area of biopsy site changes. The actual size cannot be determined with certainty. The size in the core needle biopsy, in the excisional specimen, and by imaging should be considered to determine the best size for classification. D. Multiple invasive carcinomas. If multiple carcinomas are present, the size of the largest invasive carcinoma is used for T classification. The modifier “m” is used to indicate that multiple invasive carcinomas are present. E. Multiple invasive carcinomas in close proximity. It may be difficult to distinguish multiple adjacent carcinomas from one large invasive carcinoma. Careful examination of the specimen with submission of tissue between grossly evident carcinomas is essential. Correlation with imaging findings can be helpful. F. Invasive carcinomas that have been transected. If an invasive carcinoma has been transected and is present in more than 1 tissue fragment, the sizes in each fragment should not be added together, as this may overestimate the true size. In many cases, correlation with the size on breast imaging will be helpful to choose the best size for classification. In other cases, the pathologist will need to use his or her judgment in assigning an AJCC T category.

Invasive carcinoma and DCIS (Figure 2, A): The size measurement includes only the largest area of contiguous invasion of stroma. Surrounding DCIS is not included in the size measurement.

Small invasive carcinoma with adjacent biopsy site changes (Figure 2, B and C): If the invasive carcinoma in the excision is small (ie, ≤ 1 cm) and is adjacent to a prior biopsy site, it is possible that the original size of the carcinoma was larger before biopsy. In such cases it is helpful to compare the largest size on the previous biopsy with the size of the tumor by imaging before biopsy to determine the best size for T classification. However, the sizes on the biopsy and in the excision should not be added together, as this will generally overestimate the size of the carcinoma.

Multiple invasive carcinomas (Figure 2, D): The size of the largest carcinoma is used for T classification. The sizes of multiple invasive carcinomas should not be added together. The modifier “m” is used to indicate the presence of multiple invasive carcinomas.

Multiple invasive carcinomas in close proximity (Figure 2, E): It can sometimes be difficult to distinguish 1 invasive carcinoma from multiple carcinomas very close to one another. Careful gross examination and examination of tissue between grossly evident carcinomas are required. Correlation with imaging can also be helpful. In some cases, diffusely invasive carcinoma (eg, lobular carcinoma) is not easily defined by gross examination or by imaging. The extent of invasion may be indicated by the number of blocks involved and/or the involvement of opposing margins. In some cases, the pathologist will need to use his or her best judgment in assigning the T classification.

Invasive carcinomas that have been transected (Figure 2, F): If an invasive carcinoma is transected during a procedure and is present in more than 1 fragment of tissue, it may be difficult or impossible to determine the size and/or the number of carcinomas present. If the carcinoma is present at the margin of the resection over a broad front by macroscopic examination, the carcinoma could be coded as pTX because the total extent of tumor cannot be assessed. Alternatively, a minimal T size

could be provided with a notation that the actual size may be larger. The sizes in multiple specimens of a transected carcinoma should not be added together. In such cases, the size on breast imaging may be helpful in determining the best T classification. Size should always be determined before tissue is taken for clinical assays or for investigational studies.

DCIS with microinvasion: Microinvasion is defined by the AJCC as invasion measuring 0.1 cm or less in size. If more than 1 focus of microinvasion is present, the number of foci present, an estimate of the number, or a note that the number of foci is too numerous to quantify should be reported. In some cases, immunoperoxidase studies for myoepithelial cells may be helpful to document areas of invasion and the size of the invasive foci.

F. Tumor Focality (Single or Multiple Foci of Invasive Carcinoma)

Patients with multiple foci of invasion may be divided into the following 6 groups:

- **Extensive carcinoma in situ (CIS) with multiple foci of invasion (Figure 3, A).** Extensive DCIS is sometimes associated with multiple areas of invasion. The invasive carcinomas are usually similar in histologic appearance and immunophenotype, unless the DCIS shows marked heterogeneity. This is the most common etiology of multiple invasive carcinomas.
- **Invasive carcinoma with smaller satellite foci of invasion (Figure 3, B).** A large carcinoma is sometimes surrounded by smaller adjacent foci of invasion. In such cases, the appearance of multiple foci may be due to irregular extensions of the carcinoma into stroma, which in 2 dimensions give the appearance of multiple foci. In such cases, the smaller foci are usually identical in histologic appearance and immunophenotype to the dominant carcinoma.
- **Invasive carcinoma with extensive lymph-vascular invasion (LVI) (Figure 3, C).** Additional foci of invasion may arise from areas of LVI (ie, an intramammary metastasis). The multiple carcinomas are usually identical in histologic appearance and immunophenotype.
- **Multiple biologically separate invasive carcinomas (Figure 3, D).** Some patients have multiple synchronous biologically independent carcinomas. Patients with germ-line mutations are at increased risk for developing multiple carcinomas. The carcinomas may or may not be similar in appearance and immunophenotype.
- **Invasive carcinomas after neoadjuvant therapy (Figure 3, E).** Cancers with a significant response to chemotherapy typically present as multiple residual foci within a fibrotic tumor bed (see Note K). The foci of invasion are usually identical in appearance and immunophenotype.
- **Transection of a single carcinoma into multiple fragments (Figure 3, F).** If invasive carcinoma is present in multiple fragments of a fragmented specimen, transection of 1 carcinoma should be considered. Correlation with clinical and imaging findings can sometimes be helpful to determine the best size for T classification and to determine whether or not multiple foci were present.

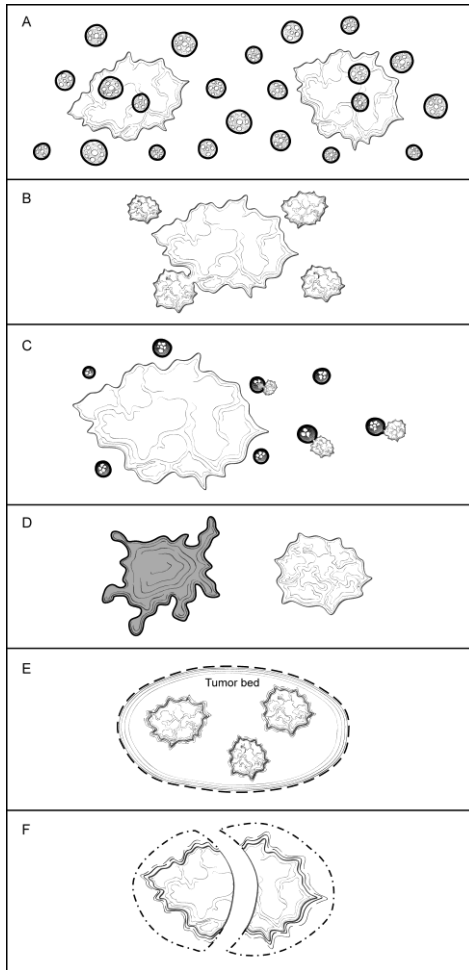


Figure 3. Multiple Invasive Carcinomas. A. Extensive carcinoma in situ with multiple foci of invasion. The invasive carcinomas are usually similar in histologic appearance and immunoprofile unless the ductal carcinoma in situ (DCIS) shows marked heterogeneity. B. Invasive carcinoma with smaller satellite foci. The smaller foci are generally within 1 to 5 mm of the main carcinoma and are most likely due to extensions of the main carcinoma that would be connected in another plane of section. The carcinomas are usually identical in appearance and immunoprofile. C. Invasive carcinoma with extensive lymph-vascular invasion. Areas of lymph-vascular invasion can give rise to additional foci of invasive carcinoma (ie, intramammary metastasis). The carcinomas are usually identical in appearance and immunoprofile. D. Multiple biologically separate invasive carcinomas. These carcinomas are usually widely separated and may be histologically and immunophenotypically distinct. E. Invasive carcinomas after presurgical (neoadjuvant) therapy. If there is a marked response to treatment, multiple foci of carcinoma may be scattered over a fibrotic tumor bed. The residual carcinoma is usually similar in appearance and immunoprofile to the pretreatment carcinoma, but in some cases alterations due to treatment may be present. F. Transection of a single carcinoma into multiple fragments. If a carcinoma is transected during excision, it may be difficult to determine if one or multiple carcinomas are present. The carcinomas should be identical in appearance and immunoprofile.

Features pertaining to a specific cancer (ie, histologic type, grade, size, and the results of ER, PR, and HER2/neu studies) should be provided for the largest invasive carcinoma in the checklist. If smaller carcinomas differ in histologic type or grade, this information should be included under “Additional Pathologic Findings,” and additional ancillary tests are recommended for these carcinomas. Features pertaining to all

carcinomas (eg, margins, lymph node status) can be reported in the body of the checklist.

Patients with multiple grossly evident invasive carcinomas have a higher risk of having lymph node metastases.¹⁰ However, it has not been shown that multiple invasive carcinomas increase the risk of distant metastases for patients with lymph node-negative disease.

AJCC T classification is based on the carcinoma with the largest T category. If there are bilateral cancers, the stage is based on the carcinoma with the higher stage. Cases with multiple foci of invasive carcinoma are indicated by the modifier “m” in AJCC classification to distinguish them from cases with a single focus of invasion.

G. Macroscopic and Microscopic Extent of Tumor

Breast cancers can invade into the overlying skin or into the chest wall, depending on their size and location. Extension into skin and muscle is used for AJCC classification, and these findings may be used for making decisions about local treatment. The extent of associated DCIS is important for determining the type of surgery that will be necessary to obtain free margins.

Skin

There are multiple ways that breast carcinoma can involve the skin:

DCIS involving nipple skin (Paget disease of the nipple) (Figure 4, A): DCIS can extend from the lactiferous sinuses into the contiguous skin without crossing the basement membrane. This finding does not change the T classification of the invasive carcinoma.

Invasive carcinoma invading into dermis or epidermis, without ulceration (Figure 4, B): Skin invasion correlates with the clinical finding of a carcinoma fixed to the skin and may be associated with skin or nipple retraction. This finding does not change the T classification.

Invasive carcinoma invading into dermis and epidermis with skin ulceration (Figure 4, C): In the past, skin ulceration was associated with very large, locally advanced carcinomas. However, skin ulceration can also be associated with superficially located small carcinomas. It is unknown if skin involvement confers a worse prognosis as compared to carcinomas of similar size without skin invasion. Carcinomas with skin ulceration are classified as T4b.

Ipsilateral satellite skin nodules (Figure 4, D): An area of invasive carcinoma within the dermis, separate from the main carcinoma, is usually associated with lymph-vascular invasion. This finding is classified as T4b.

Dermal lymph-vascular invasion (Figure 4, E): Carcinoma present within lymphatic spaces in the dermis is often correlated with the clinical features of inflammatory carcinoma (diffuse erythema and edema involving one-third or more of the breast) and such cases would be classified as T4d. In the absence of the clinical features of inflammatory carcinoma, this finding remains a poor prognostic factor but is insufficient to classify a cancer as T4d. This finding is separately documented under “Dermal Lymph-Vascular Invasion.”

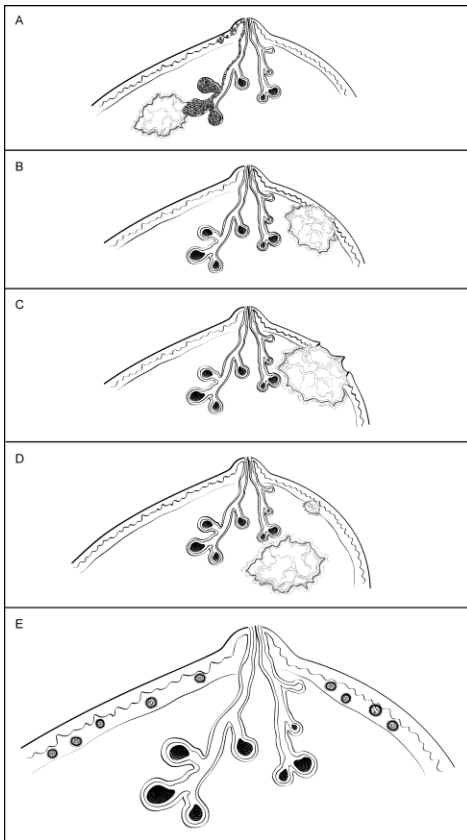


Figure 4. Invasive Carcinoma: Skin Involvement. A. Ductal carcinoma in situ (DCIS) involving nipple skin (Paget disease of the nipple) associated with an invasive carcinoma. DCIS can traverse the lactiferous sinuses into the epidermis without crossing a basement membrane. This finding does not change the T classification of an underlying invasive carcinoma. B. Invasive carcinoma invading into dermis or epidermis, without ulceration. This finding does not change the T classification of the invasive carcinoma. C. Invasive carcinoma invading into dermis and epidermis with skin ulceration. This carcinoma would be classified as T4b, unless additional features warrant classification as T4c (chest wall invasion) or T4d (inflammatory carcinoma). D. Ipsilateral satellite skin nodules. An area of invasive carcinoma in the skin, separate from the main carcinoma, is usually associated with lymph-vascular invasion. This finding is classified as T4b, unless additional features warrant classification as T4c (chest wall invasion) or T4d (inflammatory carcinoma). E. Dermal lymph-vascular invasion. If carcinoma within lymphatic spaces in the dermis is correlated with the clinical features of inflammatory carcinoma (diffuse erythema and edema involving one-third or more of the breast), the carcinoma is classified as T4d. If clinical signs are not present, this finding does not change the T classification, but is an indicator of a poor prognosis.

Muscle

Skeletal muscle may be present at the deep/posterior margin. The presence of muscle documents that the excision has extended to the deep fascia. Invasion into skeletal muscle should be reported as this finding may be used as an indication for post-mastectomy radiation therapy.

The skeletal muscle present is generally pectoralis muscle. Invasion into this muscle is not included as T4a. Invasion must extend through this muscle into the chest wall in

order to be classified as T4a. However, chest wall muscles are rarely removed in mastectomy specimens.

Ductal Carcinoma In Situ

Ductal carcinoma in situ associated with invasive carcinoma increases the risk of local recurrence. It is more important to report the features of DCIS when in situ disease is predominant (eg, cases of DCIS with microinvasion or extensive DCIS associated with T1a carcinoma). If DCIS is a minimal component of the invasive carcinoma, the features of the DCIS have less clinical relevance. Therefore, most of the reporting elements for DCIS are optional and should be used at the discretion of the pathologist.

The pathology report should specify whether extensive DCIS is present. Extensive intraductal component (EIC)-positive carcinomas are defined in 2 ways (Figure 5, A through D)¹¹:

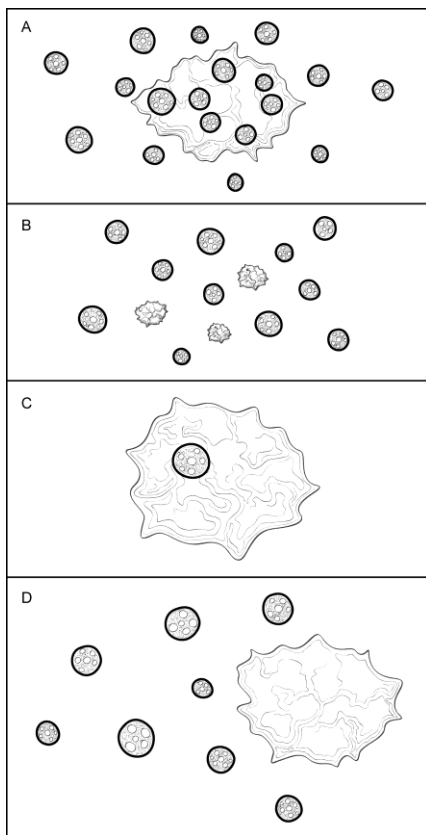


Figure 5. Extensive Intraductal Component (EIC). A. EIC-positive carcinomas are defined by the following criteria: (1) $\geq 25\%$ of the area within the invasive carcinoma is ductal carcinoma in situ (DCIS) and (2) DCIS is also present outside the area of invasive carcinoma. B. EIC-positive carcinomas also include carcinomas in which DCIS is associated with a “small” (approximately 1 cm or less) invasive carcinoma or carcinomas. C. EIC-negative carcinomas do not fulfill the criteria for being positive for EIC. D. Some carcinomas do not strictly fulfill the criteria for EIC but are associated with extensive DCIS in the surrounding tissue. In such cases it is helpful to provide some measure of the extent of DCIS in the specimen.

1. Ductal carcinoma in situ is a major component within the area of invasive carcinoma (approximately 25%) and DCIS is also present in the surrounding breast parenchyma.

2. There is extensive DCIS associated with a small (~1 cm or less) invasive carcinoma (ie, the invasive carcinoma is too small for DCIS to comprise 25% of the area).

Extensive intraductal component-positive carcinomas are associated with an increased risk of local recurrence when the surgical margins are not evaluated or focally involved. The finding of EIC positivity has less significance when DCIS does not extend close to margins.

In some cases, extensive DCIS can be present outside the area of invasive carcinoma although the carcinoma does not technically fulfill the criteria for EIC positivity. In such cases, quantification of the amount of DCIS present can be helpful.

The extent of DCIS will be most relevant for cases of extensive DCIS with microinvasion and least relevant for large EIC-negative invasive carcinomas. Methods for estimating the extent of DCIS include directly measuring the lesion when confined to a single histologic slide, determining size by submitting the entire specimen in sequence and in sections of uniform thickness, or counting the number of blocks with DCIS. The DCIS checklist provides additional information on determining the extent of DCIS.¹²

Architectural Pattern of DCIS

The architectural pattern has traditionally been reported for DCIS. However, nuclear grade and the presence of necrosis are more predictive of clinical outcome.

Nuclear Grade of DCIS

The nuclear grade of DCIS is determined using 6 morphologic features (Table 1).¹³

Table 1. Nuclear Grade of Ductal Carcinoma in Situ

Feature	Grade I (Low)	Grade II (Intermediate)	Grade III (High)
Pleomorphism	Monotonous (monomorphic)	Intermediate	Markedly pleomorphic
Size	1.5 to 2 x the size of a normal red blood cell or a normal duct epithelial cell nucleus	Intermediate	>2.5 x the size of a normal red blood cell or a normal duct epithelial cell nucleus
Chromatin	Usually diffuse, finely dispersed chromatin	Intermediate	Usually vesicular with irregular chromatin distribution
Nucleoli	Only occasional	Intermediate	Prominent, often multiple
Mitoses	Only occasional	Intermediate	May be frequent
Orientation	Polarized toward luminal spaces	Intermediate	Usually not polarized toward the luminal space

Necrosis

The presence of necrosis is correlated with the finding of mammographic calcifications (ie, most areas of necrosis will calcify). Ductal carcinoma in situ that presents as

mammographic calcifications often recurs as calcifications. Necrosis can be classified as follows:

- Central (“comedo”): The central portion of an involved ductal space is replaced by an area of expansive dirty necrosis that is easily detected at low magnification. Ghost cells and karyorrhectic debris are generally present. Although central necrosis is generally associated with high-grade nuclei (ie, comedo DCIS), it can also occur with DCIS of low or intermediate nuclear grade.
- Focal: Small foci, indistinct at low magnification, or single cell necrosis.

Necrosis should be distinguished from secretory material, which can also be associated with calcifications, but does not include nuclear debris.

H. Histologic Type of Invasive Carcinoma

This protocol applies to all invasive carcinomas of the breast. The World Health Organization (WHO) classification of breast carcinoma is presented below, although the protocol does not preclude the use of other classifications or histologic types. Carcinomas may be classified based on the H&E appearance without the use of immunohistochemical studies.

WHO Classification of Invasive Carcinoma of the Breast¹⁴

Microinvasive carcinoma

Invasive ductal carcinoma, not otherwise specified (NOS)

 Mixed type carcinoma

 Pleomorphic carcinoma

 Carcinoma with osteoclastic giant cells

 Carcinoma with choriocarcinomatous features

 Carcinoma with melanotic features

Invasive lobular carcinoma

Tubular carcinoma

Invasive cribriform carcinoma

Medullary carcinoma

Mucinous carcinomas and other tumors with abundant mucin

 Mucinous carcinoma

 Cystadenocarcinoma and columnar cell mucinous carcinoma

 Signet ring cell carcinoma

Neuroendocrine tumors

 Solid neuroendocrine carcinoma

 Atypical carcinoid tumor

 Small cell/oat cell carcinoma

 Large cell neuroendocrine carcinoma

Invasive papillary carcinoma

Invasive micropapillary carcinoma

Apocrine carcinoma

Metaplastic carcinomas

 Pure epithelial metaplastic carcinomas

 Squamous cell carcinoma

 Adenocarcinoma with spindle cell metaplasia

 Adenosquamous carcinoma

Mucoepidermoid carcinoma
 Mixed epithelial/mesenchymal metaplastic carcinomas
 Lipid-rich carcinoma
 Secretory carcinoma
 Oncocytic carcinoma
 Adenoid cystic carcinoma
 Acinic cell carcinoma
 Glycogen-rich clear cell carcinoma
 Sebaceous carcinoma
 Inflammatory carcinoma: defined clinically as an enlarged erythematous breast. Clinical features of inflammatory carcinoma must be present in order to classify a carcinoma as T4d.

I. Histologic Grade

All invasive breast carcinomas should be graded.¹⁵ The Nottingham combined histologic grade (Elston-Ellis modification of Scarff-Bloom-Richardson grading system) should be used for reporting. Within each stage grouping there is a relation between histologic grade and outcome.

The Nottingham combined histologic grade evaluates the amount of tubule formation, the extent of nuclear pleomorphism, and the mitotic count. Each variable is given a score of 1, 2 or 3, and the scores are added to produce a grade. The mitotic score is determined by the number of mitotic figures found in 10 consecutive high-power fields (HPF) in the most mitotically active part of the tumor. Only clearly identifiable mitotic figures should be counted; hyperchromatic, karyorrhectic, or apoptotic nuclei are excluded. Because of variations in field size, the HPF size must be determined for each microscope and the appropriate point score determined accordingly. It is recommended that the size be measured by using a micrometer. However, the diameter of an HPF can also be calculated by using the method below.

Measuring the Size of a High-Power Field (HPF) With a Ruler

Use a clear ruler to measure the diameter of a low-power field. This number can be used to calculate a constant based on the following formula:

$$\text{Eyepiece Magnification} \times \text{Objective Magnification} \times \text{Microscopic Field Diameter} = \text{A Constant}$$

When the value of the constant is known, the diameter of an HPF can be calculated for other objectives by using the following formula:

$$\text{Unknown Field Diameter} = \text{Constant} / (\text{Eyepiece Magnification} \times \text{Objective Magnification})$$

Half of the field diameter is the radius of the field (r), which can then be used to calculate the area of the HPF:

$$3.1415 \times r^2 = \text{Area of Microscopic Field}$$

If the microscopic field diameter or the area of the field is known, Table 2 can be used to determine the number of mitoses corresponding to different scores.

Table 2. Score Categories According to Field Diameter and Mitotic Count

Scoring Categories of Mitotic Counts				
Field diameter (mm)	Area (mm ²)	Number of mitoses per 10 fields corresponding to:		
		Score 1	Score 2	Score 3
0.40	0.125	≤4	5 to 9	≥10
0.41	0.132	≤4	5 to 9	≥10
0.42	0.139	≤5	6 to 10	≥11
0.43	0.145	≤5	6 to 10	≥11
0.44	0.152	≤5	6 to 11	≥12
0.45	0.159	≤5	6 to 11	≥12
0.46	0.166	≤6	7 to 12	≥13
0.47	0.173	≤6	7 to 12	≥13
0.48	0.181	≤6	7 to 13	≥14
0.49	0.189	≤6	7 to 13	≥14
0.50	0.196	≤7	8 to 14	≥15
0.51	0.204	≤7	8 to 14	≥15
0.52	0.212	≤7	8 to 15	≥16
0.53	0.221	≤8	9 to 16	≥17
0.54	0.229	≤8	9 to 16	≥17
0.55	0.238	≤8	9 to 17	≥18
0.56	0.246	≤8	9 to 17	≥18
0.57	0.255	≤9	10 to 18	≥19
0.58	0.264	≤9	10 to 19	≥20
0.59	0.273	≤9	10 to 19	≥20
0.60	0.283	≤10	11 to 20	≥21
0.61	0.292	≤10	11 to 21	≥22
0.62	0.302	≤11	12 to 22	≥23
0.63	0.312	≤11	12 to 22	≥23
0.64	0.322	≤11	12 to 23	≥24
0.65	0.332	≤12	13 to 24	≥25
0.66	0.342	≤12	13 to 24	≥25
0.67	0.353	≤12	13 to 25	≥26
0.68	0.363	≤13	14 to 26	≥27
0.69	0.374	≤13	14 to 27	≥28

From Pathology Reporting of Breast Disease.¹⁶ Copyright 2005 National Health Service Cancer Screening Programme and The Royal College of Pathologists. Adapted with permission.

J. Margins

Whenever feasible, the specimen should be oriented in order for the pathologist to identify specific margins. This is particularly important for excisions less than total mastectomy, where it may be necessary for the surgeon to excise residual tumor at a specific margin (eg, superior, inferior, medial, lateral, anterior, or deep). Identification of surgical margins also allows measurement of the distance between the carcinoma and specific margins. All identifiable margins should be evaluated for involvement by carcinoma both grossly and microscopically.

Orientation may be done by sutures or clips placed on the specimen surface or by other means of communication between surgeon and pathologist, and should be documented in the pathology report. Margins can be identified in several ways, including the use of multiple colored inks, by submitting the margins in specific cassettes, or by the surgeon submitting each margin as a separately excised specimen. Inks should be applied carefully to avoid penetration deep into the specimen.

Macroscopic or microscopic involvement of surgical margins by invasive carcinoma or DCIS should be noted in the report. If the specimen is oriented, the specific site(s) of involvement should also be reported. When possible, the pathologist should report the distance from the tumor to the closest margin.

If margins are sampled with perpendicular sections, the pathologist should report the distance of the invasive carcinoma and DCIS to the closest margin, whenever possible. Because of the growth pattern of DCIS in the ductal system, a negative but close margin does not ensure the absence of DCIS in the adjacent tissue.

A positive margin requires ink on carcinoma. If the specimen is oriented, the specific site(s) of involvement (eg, superior margin) should also be reported.

The deep margin may be at muscle fascia. If so, the likelihood of additional breast tissue beyond this margin (and therefore possible involvement by DCIS) is extremely small. A deep muscle fascial margin (eg, on a mastectomy specimen) positive for DCIS is unlikely to have clinical significance. However, invasive carcinoma at the deep margin, especially if associated with muscle invasion, is often an indication for postmastectomy radiation.

A superficial (generally anterior) margin may be immediately below the skin and there may not be additional breast tissue beyond this margin. However, some breast tissue can be left in skin flaps, and the likelihood of residual breast tissue is related to the thickness of the flap.¹⁷

Specimen radiography is important to assess the adequacy of excision. Compression of the specimen should be minimized, as it can severely compromise the ability to assess the distance of the DCIS from the surgical margin. Mechanical compression devices should be used with caution and preferably reserved for nonpalpable lesions that require this technique for imaging (eg, microcalcifications).

It is helpful to report the approximate extent of margin involvement:

- Unifocal: 1 focal area of carcinoma at the margin, <0.4 cm
- Multifocal: 2 or more foci of carcinoma at the margin
- Extensive: carcinoma present at the margin over a broad front (>0.5 cm)

K. Treatment Effect

Patients may be treated with endocrine therapy or chemotherapy before surgical excision (termed presurgical or neoadjuvant therapy). The response of the invasive carcinoma to therapy is a strong prognostic factor for disease-free and overall survival. Special attention to finding and evaluating the tumor bed is necessary for these specimens.¹⁸⁻²⁰

Numerous classification systems have been developed to evaluate response.^{18,19} Institutions or treatment protocols may require evaluation by one of these systems. The AJCC stage after treatment is also associated with prognosis. T and N categories determined after treatment are indicated by the prefix “yp.”

Invasive carcinomas with a minor response may show little or no change in size. With greater degrees of response, the carcinoma shows decreased cellularity and may be present as multiple foci of invasion scattered over a larger tumor bed. The AJCC T category is determined by the largest contiguous focus of invasive carcinoma. The “m” modifier is used to indicate that multiple foci of invasive carcinoma are present. The measurement should not include acellular areas of fibrosis within the tumor bed. The inclusion of additional information such as the distance over which invasive carcinoma is present, the number of foci of invasive carcinoma, or the number of slides or blocks with invasive carcinoma may be helpful in estimating the extent of residual disease. If no residual invasive carcinoma is present in the breast, the checklist can be used to report residual DCIS and/or metastatic carcinoma in lymph nodes. If there is no residual carcinoma in the breast or in the lymph nodes, then a College of American Pathologists (CAP) checklist need not be used for reporting.

Most carcinomas are of the same grade after treatment. In a few cases, the grade will be higher because of marked nuclear pleomorphism. In very rare cases, the carcinoma will be of lower grade. The prognostic significance of a change in grade after treatment has not been determined.

It is recommended that ER, PR, and HER2/neu be repeated on invasive carcinomas after treatment, as significant changes occur in a subset of carcinomas.

L. Lymph-Vascular Invasion

Lymph-vascular invasion (LVI) is associated with local recurrence and reduced survival.²¹⁻²³ Distinguishing lymphatic channels from blood vessels is unnecessary. Documenting the presence of dermal lymph-vascular invasion is particularly important because of its strong association with the clinical findings of inflammatory breast carcinoma. Strict criteria have been proposed for the diagnosis of LVI²⁴ (Table 3). Lymph-vascular invasion may be seen in stroma between uninvolved lobules and can sometimes be mistaken for DCIS if the cells completely fill the lymphatic space.

Table 3. Criteria for Lymph-Vascular Invasion (LVI)

1.	LVI must be diagnosed outside the border of the invasive carcinoma. The most common area to find LVI is within 0.1 cm of the edge of the carcinoma.
2.	The tumor emboli usually do not conform exactly to the contours of the space in which they are found. In contrast, invasive carcinoma with retraction artifact mimicking LVI will have exactly the same shape.
3.	Endothelial cell nuclei should be seen in the cells lining the space.
4.	Lymphatics are often found adjacent to blood vessels and often partially encircle a blood vessel.

Data derived from Rosen.²⁴

M. TNM and Stage Groupings

The tumor-node-metastasis (TNM) staging system maintained collaboratively by the American Joint Committee on Cancer (AJCC) and the International Union Against Cancer (UICC) is recommended.¹

Pathologic Classification

The pathologic classification of a cancer is based on information acquired before treatment supplemented and modified by the additional evidence acquired during and from surgery, particularly from pathologic examination of resected tissues. The pathologic classification provides additional precise and objective data. Classification of T, N, and M by pathologic means is denoted by use of a lower case “p” prefix (pT, pN, pM).

Pathologic T (pT): The pathologic assessment of the primary tumor (pT) generally is based on resection of the primary tumor generally from a single specimen. Resection of the tumor with several partial removals at the same or separate operations necessitates an effort at reasonable estimates of the size and extension of the tumor to assign the correct or highest pT category.

Pathologic N (pN): The pathologic assessment of regional lymph nodes (pN) ideally requires resection of a minimum number of lymph nodes to assure that there is sufficient sampling to identify positive nodes if present. The recommended number generally does not apply in cases where sentinel node has been accepted as accurate for defining regional node involvement and a sentinel node procedure has been performed. At least 1 node with *presence or absence* of cancer documented by pathologic examination is required for pathologic staging N.

Direct extension of primary tumor into a regional node is classified as node positive. A tumor nodule with a smooth contour in a regional node area is classified as a positive node. The size of the metastasis, not the size of the node, is used for the criterion for the N category.

Specialized pathologic techniques such as immunohistochemistry or molecular techniques may identify limited metastases in lymph nodes that may not have been identified without their use of the special diagnostic techniques. Single tumor cells or small clusters of cells are classified as isolated tumor cells (ITCs). The standard definition for ITCs is a cluster of cells not more than 0.2 mm in greatest diameter.

Cases with ITCs only in lymph nodes are classified as pN0. This rule also generally applies to cases with findings of tumor cells or their components by nonmorphologic techniques such as flow cytometry or DNA analysis.

Pathologic M (pM): The pathologic assignment of the presence of metastases (pM1) requires a biopsy positive for cancer at the metastatic site. Pathologic M0 is an undefined concept and the category “pM0” may not be used. Pathologic classification of the absence of distant metastases can only be made at autopsy. However, the assessment of metastases to group a patient’s disease by pathologic TNM groupings may be either clinical (cM0 or cM1) or pathologic (pM1) (eg, pTNM = pT; pN; cM or pM). Cases with a biopsy of a possible metastatic site that shows ITCs such as circulating tumor cells (CTCs) or disseminated tumor cells (DTCs), or bone marrow micrometastases detected by IHC or molecular techniques, are classified as cM0(i+) to denote the uncertain prognostic significance of these findings, and to classify the stage group according to the T and N and M0.

Post-therapy or post-neoadjuvant therapy classification (yTNM): Cases for which systemic and/or radiation therapy are given before surgery (“neoadjuvant”) or where no surgery is performed may have the extent of disease assessed at the conclusion of the therapy by clinical or pathologic means (if resection performed). This classification is useful to clinicians because the extent of response to therapy may provide important prognostic information to patients and help direct the extent of surgery or subsequent systemic and/or radiation therapy. T and N are classified by using the same categories as for clinical or pathologic staging for the disease type, and the findings are recorded by using the prefix designator “y” (eg, ycT; ycN; ypT; ypN). The “yc” prefix is used for the clinical stage after therapy, and the “yp” prefix is used for the pathologic stage for those cases that have surgical resection after neoadjuvant therapy. The M component should be classified by the M status defined clinically or pathologically prior to therapy.

Retreatment classification (rTNM): This classification is assigned when further treatment is planned for a cancer that recurs after a disease-free interval. The original stage assigned at the time of initial diagnosis and treatment does not change when the cancer recurs or progresses. The use of this staging for retreatment or recurrence is denoted with the “r” prefix (rTNM). All information available at the time of retreatment should be used in determining the rTNM stage.

Multiple tumors: When there are multiple simultaneous tumors of the same histology in one organ, the tumor with the highest T category is the one selected for classification and staging, and the multiplicity or the number of tumors is indicated in parentheses: for example, T2(m) or T2(5). For simultaneous bilateral cancers in paired organs, the tumors are classified separately as independent tumors in different organs.

Metachronous primaries: Second or subsequent primary cancers occurring in the same organ or in different organs are staged as a new cancer with the TNM system. Second cancers are not staged using the “y” prefix unless the treatment of the second cancer warrants this use.

Residual tumor and surgical margins: The absence or presence of residual tumor after treatment is described by the symbol “R.” cTNM and pTNM describe the extent of cancer in general without consideration of treatment. cTNM and pTNM can be

supplemented by the R classification, which deals with the tumor status after treatment. In some cases treated with surgery and/or with neoadjuvant therapy there will be residual tumor at the primary site after treatment because of incomplete resection or local and regional disease that extends beyond the limit or ability of resection. The presence of residual tumor may indicate the effect of therapy, influence further therapy, and be a strong predictor of prognosis. In addition, the presence or absence of disease at the margin of resection may be a predictor of the risk of recurrent cancer. The presence of residual disease or positive margins may be more likely with more advanced T or N category tumors. The R category is not incorporated into TNM staging itself. However, the absence or presence of residual tumor and status of the margins may be recorded in the medical record and cancer registry.

The R categories for the primary tumor site are:

R0	No residual tumor
R1	Microscopic residual tumor
R2	Macroscopic residual tumor
RX	Presence of residual tumor cannot be assessed

The margin status may be recorded using the following categories:

Negative margins (tumor not present at surgical margin)

Microscopic positive margin (tumor not identified grossly at the margin, but present microscopically at the margin)

Macroscopic positive margin (tumor identified grossly at the margin)

Margin not assessed

Anatomic Stage/Prognostic Groups

Stage 0	Tis	N0	M0
Stage IA	T1 [#]	N0	M0
Stage IB	T0	N1mi	M0
	T1 [#]	N1mi	M0
Stage IIA	T0	N1 ^{##}	M0
	T1 [#]	N1 ^{##}	M0
	T2	N0	M0
Stage IIB	T2	N1	M0
	T3	N0	M0
Stage IIIA	T0	N2	M0
	T1 [#]	N2	M0
	T2	N2	M0
	T3	N1	M0
	T3	N2	M0
Stage IIIB	T4	N0,N1,N2	M0
Stage IIIC	Any T	N3	M0
Stage IV	Any T	Any N	M1

[#] T1 includes T1mic.

^{##} Does not include N1mi.

N. Additional Pathologic Findings

In some cases, additional pathologic findings are important for the clinical management of patients.

If the biopsy was performed for a benign lesion and the invasive carcinoma is an incidental finding, this should be documented. An example would be the finding of DCIS with microinvasion in an excision for a large palpable fibroadenoma.

If there has been a prior core needle biopsy or excisional biopsy, the biopsy site should be sampled and documented in the report. If the intention was to completely re-excite a prior surgical site, the report should document biopsy changes at the margin that could indicate an incomplete excision. This protocol should not be used if the main area of carcinoma has been previously removed and the current specimen is a re-excision of the margins.

If multiple invasive carcinomas are present and differ in histologic type, grade, or the expression of ER, PR, or HER2/*neu*, this information should be included as text in this section.

Microcalcifications

Cancer found in biopsies performed for microcalcifications will almost always be at the site of the calcifications or in close proximity. The presence of the targeted calcifications in the specimen should be confirmed by specimen radiography. The pathologist must be satisfied that the specimen has been sampled in such a way that the lesion responsible for the calcifications has been examined microscopically. The relationship of the radiologic calcifications to the invasive carcinoma and the DCIS should be indicated.

If calcifications can be seen in the specimen radiograph but not in the initial histologic sections, deeper levels should be examined. If needed, radiographs of the paraffin block(s) may be obtained to detect calcifications remaining in the block(s). If microcalcifications cannot be confirmed by routine microscopic evaluation, polarized light may be helpful, since calcium oxalate crystals are refractile and polarizable but usually clear or tinged yellow in H&E sections. On rare occasions, calcifications do not survive tissue processing or prolonged fixation in formalin. Foreign material can sometimes simulate calcifications (eg, metallic fragments after surgery or trauma).

O. Ancillary Studies

It is recommended that ER, PR, and HER2/*neu* be determined on all invasive carcinomas.^{1,25,26} The largest invasive carcinoma should always be tested and the results reported in the protocol. However, if smaller invasive carcinomas are of different histologic type or of higher grade, performing the studies on these cancers as well is recommended. The results for smaller foci of invasive carcinoma are best reported together under “Additional Pathologic Findings.”

Other ancillary tests (eg, gene array profiling or immunoperoxidase studies for proteins other than ER, PR, or HER2/*neu*) may be done at some institutions, but these are not required or recommended for all carcinomas at this time. Results of such studies can be reported under “Other Ancillary Studies.” Fresh tissue should not be used for special studies (eg, RNA expression profiling or investigational studies) unless the invasive carcinoma is of sufficient size that histologic evaluation and ER, PR, and HER2/*neu* assessment will not be compromised.

General Comments

In addition to the results of ancillary testing, each pathology report should provide information (or such information should be available from the laboratory) concerning variables that can affect the results of the test (see College of American Pathologists Laboratory Accreditation Program, Anatomic Pathology Checklist [questions related to reporting of results only], ANP.22988).²⁷⁻²⁹ Any deviation from the laboratory's standard protocols should be recorded. Appropriate positive and negative controls should be used and evaluated. Information that should be available includes the following:

- Type of fixative, if other than buffered formalin
- Length of fixation, if other than 8 to 72 hours^{28,30}
- Other treatment of the tissue that could potentially alter immunoreactivity (eg, prior freezing, decalcification)³¹
- Antibody clone (vendor)
- Type of detection system

The results of studies performed on a prior core needle biopsy or incisional biopsy can be included in the checklist for an excisional specimen. If the results of the studies on the core needle biopsy do not show positive results, repeat studies on the excisional biopsy should be considered. If information is included from other pathology specimens, this should be clearly indicated and the accession number provided, when known.

Estrogen Receptor and Progesterone Receptor Testing by Immunohistochemistry

Scientific rationale: Normal breast epithelial cells have receptors for estrogen and progesterone and proliferate under their influence. Most breast cancers also express these receptors (typically 75% to 85% for ER) and may be stimulated to grow when these hormones are present. Removal of endogenous hormones by oophorectomy or blocking hormonal action pharmaceutically (eg, by using tamoxifen or aromatase inhibitors) can slow or prevent tumor growth and often prolongs survival.

Clinical rationale: Estrogen receptor status is determined primarily to identify patients who may benefit from hormonal therapy. It is also a minor prognostic factor. Progesterone receptor status is determined to identify a small number of carcinomas (in most series <5%) that are PR positive and ER negative but which may respond to hormonal therapy. Progesterone receptor is also a prognostic factor.

Best method: Estrogen receptor and PR status are most often determined with formalin-fixed, paraffin-embedded tissue using immunohistochemistry.

Quality assurance: There are many tissue and technical variables that can affect the results of these assays.^{28,29,32} External proficiency testing surveys for ER and PR are available from the CAP and other organizations. These surveys are invaluable tools to ensure that the laboratory assays are working as expected.

False-negative results: Failure to detect ER or PR is the greatest problem with this assay, as patients may not receive effective therapy. There are numerous reasons for false-negative results, the most common being the following:

- Exposure of the carcinoma to heat (eg, carcinomas transected by using cautery during surgery)
- Prolonged time before fixation (“ischemic time”); may result in degradation
- Type of fixative: ER is degraded in acidic fixatives such as Bouin’s and B-5. Formalin should be buffered to avoid pH values below 7.4.
- Prolonged fixation in formalin: Optimally at least 8 hours in buffered formalin.³⁰ Fixation for more than 3 weeks can diminish immunoreactivity.^{33,34}
- Decalcification: results in loss of immunoreactivity³¹
- Incorrect antigen retrieval method
- Non-optimized antigen retrieval
- Type of antibody

Most such cases can be detected or avoided by paying attention to the following:

- Normal breast tissue should be used as a positive internal control. If the normal tissue is negative, repeat studies on the same specimen or on a different specimen should be considered.
- External controls should also be utilized and are necessary for specimens in which normal breast tissue is absent.
- The findings should be correlated with the histologic type and grade of the cancer. The study should be repeated if the results are discordant (eg, ER negative tubular carcinoma or well-differentiated to moderately differentiated lobular carcinoma).
- Repetition of the assay on another specimen when the result is negative should be considered to confirm the original result (eg, a core needle and an excision).

False-positive results: False-positive results occur less frequently.³⁵ Rare reasons would be the use of an impure antibody that cross-reacts with another antigen or misinterpretation of entrapped normal cells as carcinoma. It has been suggested that highly sensitive assays may detect very low levels of ER in cancers that will not respond to hormonal therapy. However, this has not been proven by a clinical trial.

Reporting guidelines: The results of these studies are generally incorporated into the surgical pathology report or as an addendum to the report (Table 4). There are multiple methods for reporting the presence of immunoreactive cells.

Table 4. Reporting the Results of Estrogen Receptor (ER) and Progesterone Receptor (PR) Immunohistochemical Studies

Category of ER or PR result	Comments
Immunoreactive tumor cells present ($\geq 1\%$)	75% to 85% of invasive breast cancers are positive for ER or PR, including almost all well differentiated cancers and most moderately differentiated cancers. Quantification can be provided by giving an Allred score, an H score, a percentage of positive cells, or a range of positive cells (eg, >10%, 25 to 75%). If Allred or H score are provided, it is recommended that the elements comprising the score also be reported in order to compare the results to other systems.
Less than 1% immunoreactive tumor cells present	In some systems of quantification, this is considered a negative response. The response of carcinomas with very low levels of ER or PR is unknown.
No immunoreactive tumor cells present	Approximately 15% to 25% of carcinomas will be negative for ER or PR. To avoid false-negative results, appropriate internal controls and external controls should be positive. Repeat studies should be considered on another specimen, if available, to confirm.
Pending	ER and PR have been ordered and will be reported at a later date.
Not performed	ER or PR status may not be required for some patients (eg, positive results were obtained on a prior core needle biopsy).
Other	This category should be explained with a note and may include the following: <ul style="list-style-type: none"> • Insufficient invasive carcinoma on deeper levels • Immunohistochemical studies were performed on a prior core needle biopsy, but the results are not available

Definition of a negative result: The lowest limit of ER or PR positivity that should be considered “positive” has not been defined. In the Allred system (see Table 5), the survival of patients whose carcinomas had a score of 2 (corresponding to <1% weakly positive cells) was similar to that of patients whose carcinomas were completely negative for ER.³⁶ Therefore, a score of 2 was considered to be a negative result. Carcinomas with <1% positive cells and intensity scores of 2 or 3 would have a total score of 3 or 4 and be considered positive. Although it has been suggested that carcinomas with <1% positive cells should be considered negative for ER, this has not been shown conclusively.

Quantification of ER: There is a wide range of ER levels in cancers as shown by the biochemical ligand binding assay and as observed with immunoperoxidase studies. Patients whose carcinomas have higher levels of ER have improved survival when treated with hormonal therapy.^{35,36} Quantification systems may use only the proportion of positive cells or may include the intensity of immunoreactivity:

- Number of positive cells: The number of positive cells can be reported as a percentage or within discrete categories (Figure 6).

- Intensity: Refers to degree of nuclear positivity (ie, pale to dark). The intensity can be affected by the amount of protein present, as well as the antibody used and the antigen retrieval system. In most cancers, there is heterogeneous immunoreactivity with pale to darkly positive cells present.

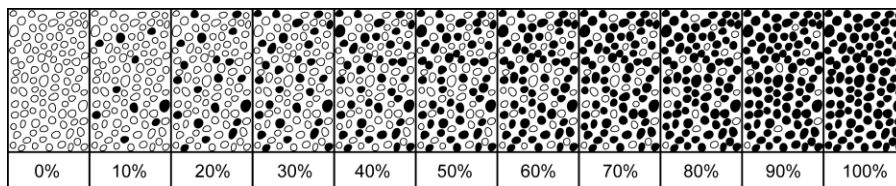


Figure 6. Quantification of immunohistochemical findings. The percentage of positive cells can be visually estimated.

Two methods of quantifying ER by using both intensity and percentage of positive cells are the Allred score³⁶ and H score³⁷ (Tables 5 and 6). The 2 systems classify carcinomas into similar, but not identical, groups³⁸ (Table 7). If high-affinity antibodies are used with sensitive detection systems, most carcinomas will fall into clearly positive (score 7 or 8) or clearly negative categories (score 0) by Allred score.^{39,40} A small group of carcinomas (<1% of total) show intermediate levels of immunoreactivity.

Quantitation can also be performed by using the proportion of positive cells. In 1 study, carcinomas were scored as 0 (<1% positive), 1 (1 to 25% positive), 2 (>25% to 75% positive), and 3 (>75% positive).⁴¹ The same results were obtained when scored by visual analysis or by image analysis. The proportion of positive cells correlated with the results of the biochemical assay and with prognosis. In another study, carcinomas with small numbers of positive cells (between 1 and 10%) had a prognosis between cancers with no or rare positive cells (<1%) and cancers with >10% positive cells.³⁵

Table 5. Allred Score for Estrogen and Progesterone Receptor Evaluation

The Allred score combines the percentage of positive cells and the intensity of the reaction product in the majority of the carcinoma. ³⁶ The 2 scores are added together for a final score with 8 possible values. A simplified Allred score groups 0 and 2, 3 and 4, 5 and 6, and 7 and 8, for 4 possible values.			
Proportion Score (PS)	% Positive Cells	Intensity Score (IS)	Intensity of Positivity
0	0	0	None
1	<1%	1	Weak
2	1% to 10%	2	Intermediate
3	11% to 33%	3	Strong
4	34% to 66%		
5	>67%		
The proportion score and intensity score are added together for a total score.			
Total Score (TS): PS + IS		Interpretation	
0, 2		Negative	
3, 4, 5, 6, 7, 8		Positive	

Table 6. H Score for Estrogen and Progesterone Receptor Evaluation

The H score is determined by multiplying the percentage of cells demonstrating each intensity (scored from 0 to 3) and adding the results. ³⁷ There are 300 possible values. In this system, <1% positive cells is considered to be a negative result.		
Calculation of H Score		
	Percentage of Cells	Value Multiplied
Cells with no signal		% x 0 = 0
Cells with weak signal		% x 1 =
Cells with moderate signal		% x 2 =
Cells with strong signal		% x 3 =
TOTAL SCORE =		

Table 7. Comparison of Allred Score and H Score

The Allred score and H score both use intensity and percentage of cells to quantify estrogen receptor (ER) expression. Allred score uses the predominant intensity and groups the percent positive cells into 5 groups, whereas H score estimates the percent positive cells for each category of signal intensity. In the H score system, <1% positive cells is a negative result. In the Allred system, if the cells show moderate or strong intensity, this would be considered a positive result (ie, a score of 3 or 4). The 2 systems give similar, but not identical, results. ³⁸				
% Cells	Intensity	Allred Score	H Score	ER Status Interpretation Allred/H Score
0	0	0+0 = 0	0	Negative
<1%	1	1+1 = 2	0	Negative
1%-10%	1	2+1 = 3	1-10	Very poor
<1%	2	1+2 = 3	0	Very poor/Negative
11%-33%	1	3+1 = 4	11-33	Poor
1%-10%	2	2+2 = 4	2-20	Poor
<1%	3	1+3 = 4	0	Poor/Negative
34%-66%	1	4+1 = 5	34-66	Poor
11%-33%	2	3+2 = 5	22-66	Poor
1%-10%	3	2+3 = 5	3-30	Poor
67%-100%	1	5+1 = 6	67-100	Intermediate
34%-66%	2	4+2 = 6	68-132	Intermediate
11%-33%	3	3+3 = 6	33-99	Intermediate
67%-100%	2	5+2 = 7	134-200	Rich
34%-66%	3	4+3 = 7	102-198	Rich
67%-100%	3	5+3 = 8	201-300	Rich

Adapted from Shousha³⁸ with permission of Blackwell Publishing Ltd, copyright 2008.

HER2/*neu* Testing by Immunohistochemistry

Scientific rationale: A subset of breast carcinomas (approximately 15% to 30%) overexpress the epidermal growth factor receptor HER2/*neu*. The mechanism of overexpression in most carcinomas is amplification of the gene resulting in increased amounts of protein. Assays for gene copy number, mRNA quantity, and protein generally give similar results. In a small subset of carcinomas (probably <5%), protein overexpression can occur by different mechanisms. Overexpression is both a prognostic and predictive factor.

Clinical rationale: The presence of HER2/*neu* is primarily evaluated to determine if a carcinoma will respond to treatment directed against the protein (eg, treatment with trastuzumab or lapatinib) and identifies patients who have a greater benefit from anthracycline-based adjuvant therapy.

Best method: HER2/*neu* protein can be detected on the membrane of tumor cells by immunohistochemical studies on formalin-fixed paraffin-embedded tissue.

Quality assurance: Factors altering the detection of HER2 by immunohistochemistry have not been studied as well as for ER and PR. Published guidelines suggested fixation for between 6 and 48 hours, but this was not based on specific data.⁴² It is recommended that tissue be fixed in buffered 10% formalin unless another fixative has been validated.

Published guidelines state that IHC results should be concordant with FISH results in 95% of cases (ie, IHC 3+ cases should show gene amplification for 95% of cases, and IHC 0 to 1+ cases should not show gene amplification for 95% of cases).⁴² Whenever possible, when both IHC and FISH are performed on the same carcinoma, the results should be correlated. When there is a major discrepancy, the most common reason is that 1 of the assays is incorrect. However, in a small number of cases there may be protein overexpression without amplification, amplification without protein overexpression, or marked intratumoral heterogeneity.

Common reasons for false-positive IHC results for HER2/*neu*:

- Overstaining may result in normal ducts and lobules showing strong positivity. The assay should be adjusted until normal cells do not show immunoreactivity, or the positivity in normal cells should be used to adjust the scoring of the tumor cells.
- Cytoplasmic positivity may obscure the membrane pattern and make interpretation difficult. In such cases, FISH studies may be helpful.
- Well-differentiated and moderately differentiated lobular carcinomas are rarely positive (<5%). However, in some cases there may be edge enhancement of individual tumor cells that may be difficult to interpret. Fluorescence in situ hybridization studies may be helpful in such cases.
- In some cases, DCIS can show stronger immunoreactivity than the associated invasive carcinoma. Care must be taken to only score the invasive component.

Common reasons for false-negative IHC results for *HER2/neu*:

- Technical problems with the assay may result in poor immunoreactivity. Appropriate controls need to be used to ensure the quality of the assay.
- Some carcinomas show marked heterogeneity. When possible, negative results on a small tumor sample (eg, in a core needle biopsy or incisional biopsy) should be confirmed on subsequent specimens with larger areas of carcinoma.

External proficiency testing surveys for *HER2* are available from the CAP and other organizations. These surveys are invaluable tools to ensure that the laboratory assays are working as expected.

Reporting guidelines: An expert panel has issued recommendations for the scoring of *HER2/neu* results by immunohistochemistry (Table 8).⁴² It is also recommended that intratumoral heterogeneity of *HER2* gene amplification be reported when present (defined as more than 5%, but less than 50% of the cells having a ratio higher than 2.2).⁴³

Table 8. Reporting Immunohistochemical Results of *HER2/neu*

IHC Score	Criteria	% of Cases	% of Cases with Amplification by FISH
0 (Negative)	No immunoreactivity or immunoreactivity in $\leq 10\%$ of tumor cells.	~ 60%	0% – 3%
1+ (Negative)	Faint weak immunoreactivity in $>10\%$ of tumor cells but only a portion of the membrane is positive.	~ 10%	0% – 7%
2+ (Equivocal)	Weak to moderate complete membrane immunoreactivity in $>10\%$ of tumor cells or circumferential intense membrane staining in $\leq 30\%$ of cells.	~ 5% – 10%	25% – 35%
3+ (Positive)	More than 30% of the tumor cells must show circumferential intense and uniform membrane staining. A homogeneous (chicken wire) pattern should be present.	~15% – 20%	95% [#]

Abbreviations: FISH, fluorescence in situ hybridization; IHC, immunohistochemistry.

[#] The expert panel increased the fraction of cells showing membrane staining from 10% to 30% to increase the concordance with gene amplification by FISH. According to the panel, cancers with 3+ results by IHC should show gene amplification in at least 95% of cases.

***HER2/neu* Testing by Fluorescence In Situ Hybridization**

Scientific rationale: Gene amplification correlates with protein overexpression in the majority (approximately 95%) of breast carcinomas.

Clinical rationale: Carcinomas with gene amplification are more likely to respond to HER2/neu directed therapy.

Best method: FISH studies for HER2/*neu* determine the number of gene copies present. Some assays report the number of HER2/*neu* genes present. In the majority of carcinomas, gene amplification occurs without duplication of chromosome 17. Therefore, the ratio of the number of *HER2* genes to the chromosome 17 number may be used to determine if gene amplification is present. It is unusual to find cases of high protein overexpression in cases with chromosomal polysomy without gene amplification.

Quality assurance: National guidelines for the performance of HER2/*neu* FISH testing have been published.⁴² CAP proficiency testing surveys are available.

Published guidelines state that FISH results should be concordant with IHC results in 95% of cases (ie, IHC 3+ cases should show gene amplification for 95% of cases, and IHC 0 to 1+ cases should not show gene amplification for 95% of cases). Whenever possible, when both IHC and FISH are performed on the same carcinoma, the results should be correlated. When there is a major discrepancy, the most common reason is that one of the assays is incorrect. However, in a small number of cases there may be protein overexpression without amplification, amplification without protein overexpression, or marked intratumoral heterogeneity.

Failure to obtain results with FISH may be due to the following:

- Prolonged fixation in formalin (>1 week)⁴⁴
- Fixation in non-formalin fixatives⁴⁵
- Procedures or fixation involving acid (eg, decalcification) may degrade DNA⁴⁶

Reporting guidelines: An expert panel has issued recommendations for HER2/*neu* reporting (Table 9).⁴²

Important issues in interpreting FISH are the following:

- Identification of invasive carcinoma: A pathologist should identify the area of the H&E slide with carcinoma to be evaluated by FISH on a corresponding level.
- Identification of associated DCIS: In some cases, DCIS will show gene amplification, whereas the associated invasive carcinoma will not. FISH analysis must be performed on the invasive carcinoma.

Some cancers have a low level of HER2 expression as determined by equivocal results by both IHC and FISH analysis. Repeat testing may be helpful to exclude possible technical problems with the assays but often does not result in definitive positive or negative results.

Table 9. Reporting the Results of FISH Studies for HER2/neu

FISH Result	Criteria	Comments
Positive for amplification	>6.0 gene copies or >2.2 ratio	>6.0 gene copies can be present with a ratio <2.2, if polysomy is present. In addition to the ratio, the number of genes and the number of chromosome 17 should be reported when these are determined as part of the assay.
Equivocal for amplification	4.0 to 6.0 genes or 1.8 to 2.2 ratio [#]	The guidelines suggest counting additional cells for FISH, retesting, or performing IHC.
Negative for amplification	<4.0 genes or <1.8 ratio	

[#] Patients with a ratio of 2.0 or greater have been eligible for Herceptin trials.

Multigene Expression Assays

Scientific rationale: Breast cancers vary greatly in histologic appearance, expression of biomarkers, response to treatment, and prognosis. Assays that detect variations in gene expression by mRNA levels have confirmed the diversity of gene expression patterns underlying these observations.

Clinical rationale: It may be possible to use multigene assays to better predict overall prognosis, response to treatment, and the likelihood of response to specific treatments.⁴⁷

Best methods: Multigene assays are offered by private companies. The proprietary nature of these assays precludes their performance in other laboratories. Microarray assays detect expression patterns by hybridizing labeled mRNA isolated from frozen tissue to microarray chips. Numerous gene products can be examined simultaneously. RT-PCR assays amplify mRNA from a few specific genes and can therefore be performed on formalin-fixed tissue. Examples of available assays:

Oncotype DX[®] Breast Cancer Assay (Genomic Health Inc, Redwood City, California): This test is appropriate for women with Stage I or II node negative and ER positive breast cancer. It is an RT-PCR based assay for 21 genes (16 cancer related genes and 5 control genes), including ER, PR, and HER2/*neu*. A recurrence score is generated that predicts the risk of recurrence at 10 years for women treated with tamoxifen. Women who have carcinomas with high recurrence scores may benefit most from the addition of CMF (cyclophosphamide, methotrexate, and 5-fluorouracil) chemotherapy, whereas women with low recurrence scores may be less likely to have a benefit. Individual values for ER, PR, and HER2/*neu* are provided.

MammaPrint[®] (Agendia BV, Amsterdam, The Netherlands): This test is offered for women under the age of 61 with ER positive or ER negative carcinomas with negative lymph nodes. This microarray assay is performed only on fresh tissue containing at least 30% tumor cells and must be collected in a kit and received by the company within 5 days from excision. It uses a 70-gene RNA profile to identify a poor prognosis signature and a good prognosis signature.

Breast Cancer Gene Expression Ratio Assay (or H:I Ratio Test) (Quest Diagnostics, Madison, New Jersey): This assay is designed for patients with ER positive, lymph node negative, carcinomas. This is an RT-PCR assay for 6 genes (2 cancer-related genes and 4 control genes) and is performed on formalin fixed paraffin embedded tissue. The ratio of the expression of homeobox gene-B13 (*HOXB13*) to the interleukin-17B receptor gene (*IL17BR*) separates carcinomas into high-risk and low-risk groups.

Rotterdam Signature (Erasmus University Cancer Center in Rotterdam, The Netherlands): This assay is relevant for women with lymph node negative carcinomas that are either ER negative or ER positive. It is a 76-gene microarray assay that does not overlap with the Oncotype DX or MammaPrint assays. The assay requires whole sections of frozen tissue.

Quality assurance: Because these tests can only be performed by the company that has patented the test, quality assurance must be maintained within the company.

Reporting guidelines: Each company issues a report of the results. Pathologists may choose to incorporate this information into their own reports if this would make the information more accessible for patient care.

P. Clinical Information

It is a Joint Commission (formerly Joint Commission on Accreditation of Healthcare Organizations [JCAHO]; www.jointcommission.org/) requirement that clinical information be provided for pathology specimens. Relevant clinical information is often necessary for the accurate evaluation of breast specimens and includes:

Patient information:

- Family history of breast or ovarian cancer and/or *BRCA1* or *BRCA2* mutation
- Current pregnancy or lactation
- Prior breast biopsy or surgery (including implants)
- Prior breast cancer diagnosis (type, location in breast, date of diagnosis)
- Prior treatment that could affect the breast:
 - Radiation
 - Chemotherapy (neoadjuvant or adjuvant)
 - Hormonal therapy (eg, tamoxifen, aromatase inhibitors, or oral contraceptives)
- Systemic diseases that may affect the breast (eg, collagen vascular disease, sarcoidosis, Wegener granulomatosis)

Specimen information:

- Type of lesion sampled (may include more than 1 of the following)
 - Palpable mass
 - Nipple discharge
 - Nipple lesion (eg, scaling crust)
 - Imaging finding
 - Mammographic or ultrasound mass: shape of mass (irregular, circumscribed, ill-defined, cystic or solid)

- Mammographic calcifications
- Mammographic architectural distortion
- Prior core needle biopsy site, with or without a clip, with or without residual radiologic or clinical lesion
- MRI-detected lesion
- Type of specimen:
 - Excision without wire localization
 - Excision with wire localization; for these specimens, the specimen radiograph with an interpretation should be made available to the pathologist
 - Nipple duct excision
 - Total mastectomy
 - Lymph node specimen (sentinel node, nonsentinel node, limited axillary dissection, complete axillary dissection)

References

1. Edge SB, Byrd DR, Carducci MA, Compton CC, eds. *AJCC Cancer Staging Manual*. 7th ed. New York, NY: Springer; 2009.
2. Association of Directors of Anatomic and Surgical Pathology. Immediate management of mammographically detected breast lesions. *Hum Pathol*. 1993;24:689-690.
3. Connolly JL, Schnitt SJ. Evaluation of breast biopsy specimens in patients considered for treatment by conservative surgery and radiation therapy for early breast cancer. *Pathol Annu*. 1988;23(pt 1):1-23.
4. Schnitt SJ, Wang HH. Histologic sampling of grossly benign breast biopsies: how much is enough? *Am J Surg Pathol*. 1989;13:505-512.
5. Schnitt SJ, Connolly JL. Processing and evaluation of breast excision specimens: a clinically oriented approach. *Am J Clin Pathol*. 1992;98:125-137.
6. Lester SC. *Manual of Surgical Pathology*. 2nd ed. New York, NY: Elsevier; 2006.
7. Viale G, Dell'Orto P, Biasi MO, et al. Comparative evaluation of an extensive histopathologic examination and a real-time reverse-transcription-polymerase chain reaction assay for mammaglobin and cytokeratin 19 on axillary sentinel lymph nodes of breast carcinoma patients. *Ann Surg*. 2008;247:136-142.
8. Julian TB, Blumencranz P, Deck K, et al. Novel intraoperative molecular test for sentinel lymph node metastases in patients with early-stage breast cancer. *J Clin Oncol*. 2008;26:3338-3345.
9. Singletary SE, Greene FL, Sobin LH. Classification of isolated tumor cells: clarification of the 6th edition of the American Joint Committee on Cancer Staging Manual. *Cancer*. 2003;90:2740-2741.
10. Andea AA, Wallis T, Newman LA, Bouwman D, Dey J, Visscher DW. Pathologic analysis of tumor size and lymph node status in multifocal/multicentric breast carcinoma. *Cancer*. 2002;94:1383-1390.
11. Morrow M, Harris JR. Local management of invasive breast cancer (chapter 33). In: Harris JR, Lippman ME, Morrow M, Osborne KE, eds. *Diseases of the Breast*. 2nd ed. Philadelphia, PA: Lippincott Williams & Wilkins; 2000: 522-523.
12. Lester SC, Bose S, Chen Y-Y, et al. Protocol for the examination of specimens from patients with ductal carcinoma in situ of the breast. *Arch Pathol Lab Med*. 2009;133:15-25.
13. Schwartz GF, Lagios MD, Carter D, et al. Consensus conference on the classification of ductal carcinoma in situ. *Cancer*. 1997;80:1798-1802.

14. Tavassoli FA, Devilee P, eds. *World Health Organization Classification of Tumours: Pathology and Genetics of Tumours of the Breast and Female Genital Organs*. Lyon, France: IARC Press; 2003.
15. Ellis IO, Elston CW. Histologic grade (chapter 19). In: O'Malley FP, Pinder SE, eds. *Breast Pathology*. Philadelphia, PA: Elsevier; 2006: 225-233.
16. *Pathology Reporting of Breast Disease*. A Joint Document Incorporating the Third Edition of the NHS Breast Screening Programme's *Guidelines for Pathology Reporting in Breast Cancer Screening* and the Second Edition of The Royal College of Pathologists' *Minimum Dataset for Breast Cancer Histopathology* Published by the NHS Cancer Screening Programmes jointly with The Royal College of Pathologists. NHSBSP Publication No 58. January 2005. Available at: <http://www.cancerscreening.nhs.uk/breastscreen/publications/nhsbsp58.html>. Accessed April 8, 2009.
17. Torresan RZ, dos Santos CC, Okamura H, Alvarenga M. Evaluation of residual glandular tissue after skin-sparing mastectomies. *Ann Surg Oncol*. 2005;12(12):1037-1044.
18. Sahoo S, Lester SC. Pathology of breast carcinomas after neoadjuvant chemotherapy. An overview with recommendations on specimen processing and reporting. *Arch Pathol Lab Med*. 2009;133:633-642.
19. Kuroi K, Toi M, Tsuda H, Kurosumi M, Akiyama F. Issues in the assessment of the pathologic effect of primary systemic therapy for breast cancer. *Breast Cancer*. 2006;13:38-48.
20. Pinder SE, Provenzano E, Earl H, Ellis IO. Laboratory handling and histology reporting of breast specimens from patients who have received neoadjuvant chemotherapy. *Histopathology*. 2007;50:409-417.
21. Gonzalez MA, Pinder SE. Invasive carcinoma: other histologic prognostic factors – size, vascular invasion and prognostic index (chapter 20). In: O'Malley FP, Pinder SE, eds. *Breast Pathology*. Philadelphia, PA: Elsevier; 2006: 235-240.
22. Lee A, DeLellis R, Silverman M, Heatley GJ, Wolfe H. Prognostic significance of peritumoral lymphatic and blood-vessel invasion in node-negative carcinoma of the breast. *J Clin Oncol*. 1990;8:1457-1465.
23. Pinder S, Ellis IO, O'Rourke S, et al. Pathological prognostic factors in breast cancer. Vascular invasion: relationship with recurrence and survival in a large series with long-term followup. *Histopathology*. 1994;24:41-47.
24. Rosen PP. Tumor emboli in intramammary lymphatics in breast carcinoma: pathologic criteria for diagnosis and clinical significance. *Pathol Annu*. 1983;18 Pt 2:215-232.
25. Harris L, Fritsche H, Mennel R, et al. American Society of Clinical Oncology 2007 update of recommendations for the use of tumor markers in breast cancer. *J Clin Oncol*. 2007;25(33):1-26.
26. National Comprehensive Cancer Network (NCCN) Practice Guideline in Oncology, v.1.2009. Available at: www.nccn.org/professionals/physician_gls/PDF/breast.pdf. Accessed April 8, 2009.
27. Commission on Laboratory Accreditation. Laboratory Accreditation Program. Anatomic Pathology Checklist. Northfield, IL: College of American Pathologists; Sept 2007. ANP.22988. Available at <http://www.cap.org/apps/cap.portal?nfpb=true&pageLabel=eLABLAPpage>. Accessed April 8, 2009.

28. Yaziji H, Taylor CR, Goldstein NS, et al. Consensus recommendations on estrogen receptor testing in breast cancer by immunohistochemistry. *Appl Immunohistochem Mol Morphol*. 2008;16:513-520.
29. Gown AM. Current issues in ER and HER2 testing by IHC in breast cancer. *Mod Pathol*. 2008;21:S8-S15.
30. Goldstein NS, Ferkowicz M, Odish E, Mani A, Hastah F. Minimum fixation time for consistent estrogen receptor immunohistochemical staining of invasive breast carcinoma. *Am J Clin Pathol*. 2003;120:86-92.
31. Arber JM, Arber DA, Jenkins KA, Battifora H. Effect of decalcification and fixation in paraffin-section Immunohistochemistry. *Appl Immunohistochem*. 1996;4:241-248.
32. Allred DC. Problems and solutions in the evaluation of hormone receptors in breast cancer. *J Clin Oncol*. 2008;26:2433-2435.
33. Arber DA. Effect of prolonged formalin fixation on the immunohistochemical reactivity of breast markers. *Appl Immunohistochem Mol Morphol*. 2002;10:183-186.
34. Oyama T, Ishikawa Y, Hayashi M, et al. The effects of fixation, processing and evaluation criteria on immunohistochemical detection of hormone receptors in breast cancer. *Breast Cancer*. 2007;14:182-188.
35. Viale G, Regan MM, Maiorano E, et al. Prognostic and predictive value of centrally reviewed expression of estrogen and progesterone receptors in a randomized trial comparing letrozole and tamoxifen adjuvant therapy for postmenopausal early breast cancer: BIG 1-98. *J Clin Oncol*. 2007;25:3846-52.
36. Harvey JM, Clark GM, Osborne CK, et al. Estrogen receptor status by immunohistochemistry is superior to the ligand binding assay for predicting response to adjuvant endocrine therapy in breast cancer. *J Clin Oncol*. 1999;17:1474-1481.
37. McCarty KS Jr, Miller LS, Cox EB, et al. Estrogen receptor analyses: correlation of biochemical and immunohistochemical methods using monoclonal antireceptor antibodies. *Arch Pathol Lab Med*. 1985;109:716-721.
38. Shousha S. Oestrogen receptor status of breast carcinoma: Allred/H score conversion table. *Histopathology*. 2008;53:346-347.
39. Collins LC, Botero ML, Schnitt SJ. Bimodal frequency distribution of estrogen receptor immunohistochemical staining results in breast cancer: an analysis of 825 cases. *Am J Clin Pathol*. 2005;123:16-20.
40. Nadji M, Gomez-Fernandez C, Ganjei-Azar P, Morales AR. Immunohistochemistry of estrogen and progesterone receptors reconsidered: experience with 5,993 breast cancers. *Am J Clin Pathol*. 2005;123:21-7.
41. Turbin DA, Leung S, Cheang MCU, et al. Automated quantitative analysis of estrogen receptor expression in breast carcinoma does not differ from expert pathologist scoring: a tissue microarray study of 3,484 cases. *Breast Cancer Res Treat*. 2008;110:417-426.
42. Wolff AC, Hammond ME, Schwartz JN, et al. American Society of Clinical Oncology/College of American Pathologists guideline recommendations for human epidermal growth factor receptor 2 testing in breast cancer. *Arch Pathol Lab Med*. 2007;131:18-43.
43. Vance GH, Barry TS, Bloom KJ, et al. Genetic heterogeneity in HER2 testing in breast cancer: panel summary and guidelines. *Arch Pathol Lab Med*. 2009;133:611-612.

44. Selvarajan S, Bay B-H, Choo A, et al. Effect of fixation period on HER2/neu gene amplification detected by fluorescence in situ hybridization in invasive breast carcinoma. *J Histochem Cytochem.* 2002;50:1693-1696.
45. Willmore-Payne C, Metzger K, Layfield LJ. Effects of fixative and fixation protocols on assessment of Her-2/neu oncogene amplification status by fluorescence in situ hybridization. *Appl Immunohistochem Mol Morphol.* 2007;15:84-87.
46. Brown RS, Edwards J, Bartlett JW, Jones C, Dogan A. Routine acid decalcification of bone marrow samples can preserve DNA for FISH and CGH studies in metastatic prostate cancer. *J Histochem Cytochem.* 2002;50:113-115.
47. Ross JS, Hatzis C, Symmans WF, Pusztai L, Hortobagyi GN. Commercialized multigene predictors of clinical outcome for breast cancer. *Oncologist.* 2008;13:477-493.